

Database of questions for the Medical-Dental Final
Examination (LDEK)
Endodontics & Restorative dentistry

Question nr 1

Which of the following adhesives are part of self-etching adhesive systems?

- A. Scotchbond and All-Bond 2.
- B. Xeno III and Prompt L-Pop.
- C. OptiBond FL and Scotchbond.
- D. OptiBond Solo Plus and Prompt L-Pop.
- E. All-Bond 2 and Xeno III.

Question nr 2

Which of the following contains **false** information concerning tetracycline discoloration of the teeth?

- A. its severity depends on the total dose of the antibiotic.
- B. its severity depends on the duration of exposure to the drug.
- C. its severity depends on the type of tetracycline used.
- D. discoloration can vary from yellow-orange to dark blue-gray.
- E. only developing teeth, before eruption, become discolored.

Question nr 3

Which answer sets the ingredients of gutta percha cones in the **descending** order of their content?

- 1) gutta-percha;
- 2) radiopacifiers;
- 3) zinc oxide;
- 4) plasticizers.

The correct answer is:

A. 1,2,3,4.

B. 1,3,4,2.

C. 2,4,3,1.

D. 3,1,2,4.

E. 3,1,4,2.

Question nr 4

Which of the following is part of the fifth generation adhesives?

A. 37% citric acid.

B. 37% phosphoric acid.

C. 15% phosphoric acid.

D. silorane.

E. 2% polyacrylic acid.

Question nr 5

Which of the following structures protect the hard tissues of the tooth against the development of internal resorption?

A. dental pulp, odontoblast layer.

B. odontoblast layer, predentine.

C. predentine, secondary dentine.

D. primary dentine, root cementum.

E. root cementum, periodontal ligament.

Question nr 6

Indicate the true statements concerning circumferential filing:

1) it can be used for preparing wide root canals;

2) it is particularly beneficial for the preparation of root canals that are round in cross-section;

3) it involves sequential insertion and withdrawal of the instrument into and from the canal;

4) pressure is only exerted on two contralateral walls of the root canal.

The correct answer is:

A. 1,3.

B. 1,2,3.

C. 1,3,4.

D. only 1.

E. only 3.

Question nr 7

Which tooth from the following is the longest human tooth?

A. maxillary right canine.

B. mandibular right canine.

C. maxillary left canine.

D. mandibular left canine.

E. maxillary canine.

Question nr 8

Indicate **the false** statement concerning the carious process:

A. carious lesion is the product of disequilibrium between demineralisation and remineralisation.

B. highly anaerobic and anaerobic environment provides an ideal niche for cariogenic bacteria.

C. bacteria quickly colonize the smooth surfaces of newly erupted teeth, because the shape of the surface contributes to their high susceptibility to caries.

D. cariogenic potential of microorganisms increases as a result of bacterial dysbiosis in the dental biofilm.

E. bacteria slowly colonize pits and fissures of newly erupted teeth, because these are harder to reach places than smooth surfaces.

Question nr 9

Maxillary sinusitis is probably the most common extraoral cause of pain in patients visiting dental clinics. Which of the following are the most characteristic of sinusitis and may help differentiate it from pulpal pain?

- 1) pain aggravation upon leaning forward quickly (headache);
- 2) biting sensitivity (“teeth are too long”);
- 3) tooth sensitivity to percussion;
- 4) tooth hypersensitivity to cold;
- 5) pain transfer to adjacent teeth.

The correct answer is:

- A.** 1,3.
- B.** 2,5.
- C.** 1,4.
- D.** 1,5.
- E.** 3,5.

Question nr 10

A 63-year-old patient reports with severe pain of tooth 43. The pain, lasting for about 2 weeks, arises while consuming warm food. A clinical examination reveals: tooth 43 no pain on percussion, normal reaction to ethyl chloride. No pathological changes on radiograph. The most probable diagnosis is:

- A.** irreversible pulpitis with vital pulp.
- B.** pulp necrosis (pulp gangrene).
- C.** acute apical periodontitis.
- D.** chronic apical periodontitis.
- E.** dentine hypersensitivity.

Question nr 11

Indicate the true statements concerning the endodontic treatment with ProTaper system:

- 1) this technique is dedicated to the preparation of narrow and curved canals;
- 2) these tools are available in manual and machine versions;
- 3) the cross-section of F2 tools is a convex triangle shape;

4) the ProTaper system is recommended for the preparation of the apical part of root canals;

5) SX tools are 19 mm, 21 mm and 25 mm in length.

The correct answer is:

A. 1,2,3.

B. 3,4,5.

C. 1,3,5.

D. 2,4,5.

E. 1,2,4.

Question nr 12

In a female patient endodontic treatment of tooth 11 was performed. It has been planned to restore the crown with the use of composite fiber reinforced post. What is the minimal distance from the root apex to the cemented post, which allows for sufficient sealing of the apical region?

A. 2-3 mm.

B. 3-4 mm.

C. 4-5 mm.

D. 5-6 mm.

E. 6-7 mm.

Question nr 13

Which of the following properties of microscope **are not** important in the removal of broken endodontic files from the root canal space?

A. magnification of the operation field.

B. dentist's ergonomic work position.

C. very good illumination of the operation field.

D. shortening of working time.

E. work in a shadeless operation field.

Question nr 14

Indicate the correct sentences concerning direct pulp capping:

- 1) dentine bridge forms two weeks after MTA application;
- 2) hardening $\text{Ca}(\text{OH})_2$ does not initiate a dentin bridge formation;
- 3) it is not recommended to perform this procedure if the tooth gives a positive response to percussion test;
- 4) NaOCl can be used as a hemostatic agent;
- 5) it is not recommended to use MTA in the case of carious pulp exposure.

The correct answer is:

- A. 1,2,3.
- B. 2,3,4.
- C. 3,4,5.
- D. 1,3,4.
- E. 1,2,5.

Question nr 15

The indications for the root canal re-treatment include:

- A. inadequate root canal filling.
- B. unhealed periradicular lesion.
- C. draining fistula.
- D. pain symptoms.
- E. all of the above.

Question nr 16

Which of the following are characteristic of dentinogenesis imperfecta type 2 on radiographs?

- 1) short roots;
- 2) long roots;
- 3) pulpal obliteration;
- 4) small bulbous crowns;
- 5) big bulbous crowns.

The correct answer is:

- A. 1,3,5.

B. 2,3,5.

C. 2,3,4.

D. 1,3,4.

E. 1,4.

Question nr 17

What is the role of orthodontic rings in the placement of the rubber dam?

A. they are rubber dam retaining elements.

B. they are retaining elements for rubber dam frames.

C. stabilization of the tooth structure for significantly damaged clinical crowns.

D. sealing the rubber dam.

E. turning around of the rubber dam toward the gingiva sulcus.

Question nr 18

Indicate the direction in which the apical part of the lingual root of the upper first molar is curved:

A. mesially.

B. distally.

C. buccally.

D. lingually.

E. root is straight and is not curved.

Question nr 20

When, during the process of dental plaque development, do the structures called palisades of cocci appear?

A. after 1 hour.

B. after 24 hours.

- C. after 3 days.
- D. after about 1 week.
- E. never.

Question nr **21**

Indicate the true statements concerning recurrent caries:

- A. it concerns non vital teeth.
- B. it has an uncontrolled course.
- C. it is localized around or under the filling.
- D. it requires a skillful dentist to prepare a cavity.
- E. it doesn't develop on a root surface.

Question nr **22**

The criteria for proper canal preparation include:

- A. developing a continuously tapered funnel.
- B. maintaining the apical foramen in its original position.
- C. keeping the apical foramen closed.
- D. A and B are correct.
- E. A, B and C are correct.

Question nr **23**

On the basis of the data given below, indicate the mean DMFT index for the population of 10 people (DMFT index value for each person is: 3,5,0,0,0,7,0,0,12,8):

- A. mean DMFT index 9.0.
- B. mean DMFT index 5.5.
- C. mean DMFT index 7.0.
- D. mean DMFT index 3.5.

E. mean DMFT index 2.5.

Question nr 24

Indicate the correct statement concerning microfill composites:

- A.** these materials require longer light curing.
- B.** these materials have worse mechanical properties (resistance) than hybrid composite resin materials.
- C.** they contain less filler than macrofill composite resin materials.
- D.** the diameter of filler particles is $< 0.1 \mu\text{m}$.
- E.** all of the above.

Question nr 25

On the orthopantomogram (OPG) of a 28-year-old patient an obliteration of the pulp chamber of tooth 22 as well as a widening of the periodontal ligament space in the periapical region was observed. The tooth did not respond to ethyl chloride; percussion test was negative. The crown of the tooth compared with the adjacent teeth was more yellow. The patient did not report spontaneous pain. What is the most likely reason for the changes in tooth 22?

- A.** physiological changes related to aging.
- B.** reversible pulpitis in the course of chronic caries.
- C.** state after prolonged treatment with zinc oxide with eugenol.
- D.** trauma-related replacement resorption.
- E.** changes related to orthodontic treatment (fixed appliance).

Question nr 26

Cleaning of the chamber after the canal system obturation with the use of a resin sealer should be performed with cotton pellets soaked in:

- A.** EDTA.
- B.** NaOCl.
- C.** saline.

D. alcohol.

E. chlorhexidine.

Question nr 27

What kind of caries does the following description concern: "Sometimes, for unknown reasons, chronic caries stops for many years. Very often it is observed on the proximal surface, after an extraction of the neighboring tooth, which makes the affected surface easier to clean and more accessible to saliva"?

A. secondary caries.

B. arrested caries.

C. rampant caries.

D. circular caries.

E. deep caries.

Question nr 28

Indicate the correct definition of the physiological foramen:

A. it is a root canal constriction in the distance of 0.5-2 mm away from the anatomic foramen of the root.

B. it is the apex of the root.

C. it is the anatomic foramen.

D. it is the radiographic apex.

E. none of the above.

Question nr 29

Indicate disadvantages of the intrapulpal injection used in endodontic treatment:

A. short time of anesthesia.

B. necessity of pulp chamber trepanation and pulp exposure in a patient suffering from irreversible pulpitis.

C. patient's strong discomfort at the moment of the needle insertion into the pulp.

D. severe painfulness of the procedure because of a direct application of anesthetics into the very sensitive and vital pulp.

E. all the above.

Question nr 30

Which of the following are part of the DIFOTI system?

- 1) laser light source;
- 2) fiber optic lamp;
- 3) AC power source;
- 4) source emitting light of 655 nm wavelength;
- 5) optical fiber;
- 6) digital camera;
- 7) computer.

The correct answer is:

A. 1,2,3,6.

B. 2,3,5,6.

C. 1,5,6,7.

D. 3,4,6,7.

E. 2,4,5,7.

Question nr 31

Copper-enriched amalgams:

A. contain about 40% of copper in their composition.

B. do not release mercury.

C. allow to completely eliminate silver-mercury phase.

D. are not corroding.

E. are more resistant to fractures than conventional amalgams.

Question nr 32

The recommended time for EDTA to be left in the canal in order to remove

the smear layer is:

- A. 10 seconds.
- B. 30 seconds.
- C. 1 minute.
- D. 2 minutes.
- E. 5 minutes.

Question nr **33**

A 22-year-old male patient complains of a pain in tooth 22 that awakened him at 4:00 AM and still persists. The intraoral examination revealed the presence of a clinically acceptable, extensive filling on the distal surface of tooth 22. The patient reports that the filling was placed a month ago and the procedure was performed under anesthesia. In the described situation it is advisable to:

- A. exclude the tooth from occlusion and order a painkiller, and observe the tooth.
- B. remove the filling, apply an odontotropic material and temporary filling, and observe the tooth.
- C. perform pulp extirpation under anesthesia and implement RCT.
- D. replace the filling with glass-ionomer.
- E. implement open treatment and order nonsteroidal antiinflammatory drugs (NSAIDs).

Question nr **34**

Which of the following are the **contraindication** to teeth whitening using the overlay method?

- 1) dentinal hypersensitivity;
- 2) gum recession;
- 3) porcelain veneer;
- 4) all-ceramic crown;
- 5) pregnancy;
- 6) metal crown.

The correct answer is:

- A. 1,2,5.

B. 1,3,6.

C. 2,3,4.

D. 2,3,5.

E. 4,5,6.

Question nr 35

What is the maximum acceptable distance between the tip of the cone and the preparation range visible on the X-ray taken before the root canal obturation during gutta-percha fitting with the use of the lateral condensation technique?

A. 0.5-1 mm.

B. 2-2.5 mm.

C. 3-3.5 mm.

D. 4-4.5 mm.

E. 5-5.5 mm.

Question nr 36

Why is the rubber dam in dark colors preferred when carious lesions are prepared and filled?

A. it is the thickest and most resistant.

B. it is easier to fix.

C. it creates smaller forces detaching the retainer from the tooth.

D. it contrasts well with the teeth and improves the visibility of the tooth chamber.

E. it adheres to the tooth tighter.

Question nr 37

Which factor is meaningless when it comes to assess the risk of new carious lesions?

A. heavy plaque deposits on the teeth.

- B.** orthodontic braces.
- C.** reduced salivary flow.
- D.** incipient lesions on smooth surfaces.
- E.** all the listed factors are important.

Question nr **38**

What is the main advantage of titanium nitride coated instruments used for filling cavities with composite materials?

- A.** they are ergonomic.
- B.** material doesn't stick to them.
- C.** they are well tolerated by patients.
- D.** they are very flexible.
- E.** their wear is slow.

Question nr **39**

Indicate the true statements concerning instruments used for the preparation of root canals:

- 1) three- or four-step series of rotational movements of Flex-R files is related to the balanced force technique;
- 2) three- or four-step series of rotational movements of Flex-R files is related to the hybrid technique;
- 3) cross sections of a Profile instrument show a U-shape design;
- 4) cross sections of a Protaper instrument show a U-shape design.

The correct answer is:

- A.** 1,3.
- B.** 1,4.
- C.** 2,3.
- D.** 2,4.
- E.** only 1.

Question nr **40**

What is the minimal size of endodontic files which should be used for root canal preparation to ensure proper penetration of irrigants?

- A.** 15.
- B.** 25.
- C.** 35.
- D.** 45.
- E.** 50.

Question nr 41

The highest probability of incomplete analgesia, despite applying proper anesthesia techniques in the case of irreversible pulpitis is in the tooth:

- A.** 37.
- B.** 41.
- C.** 22.
- D.** 24.
- E.** 15.

Question nr 42

A female patient aged 22 presented to the dental surgery in order to treat Black's class II carious cavity on the occlusal and distal surface of tooth 45. After preparation of the cavity, a carious white spot was noted on the mesial surface of tooth 46 with an intact enamel surface. The X-ray was taken and it revealed a small demineralization just below the enamel. No more active carious cavities were present in the patient and the oral hygiene was optimal. What kind of treatment can you propose in the case of tooth 46?

- A.** preparation of the cavity and filling with GIC.
- B.** preparation of the cavity with the key-hole technique and filling the cavity with composite resin.
- C.** tunnel preparation and filling the cavity with GIC.
- D.** remineralization and clinical and radiological control.

E. tooth observation.

Question nr **43**

Irrigants are unable to reach the apical part of the root if the canal **is not** enlarged to the size of ISO:

A. 10.

B. 15.

C. 20.

D. 25.

E. 35.

Question nr **44**

The minimum thickness of a zinc oxide temporary filling layer used for protecting the tooth during endodontic treatment is:

A. 0.5 mm.

B. 1 mm.

C. 3.5-4 mm.

D. 5-6 mm.

E. 7-9 mm.

Question nr **45**

Which of the following statements concerning the adhesion of composite resin materials to dentin is true?

A. achieving reliable adhesion to the layers of dentin that lie adjacent to the pulp is more difficult, as the number of dentinal tubules and their diameter is bigger in the pulp area than in the areas located further away from the pulp.

B. achieving adhesion to the layers of dentin that lie adjacent to the pulp is easier due to the lower surface wetness of dentin in this area caused by lower amounts of tubular fluid.

C. dentin is a hydrophobic tissue, therefore achieving mechanical adhesion

to dentin does not pose clinical difficulties.

D. it is possible to achieve the adhesion of composite resin materials to dentin without removing or modifying the smear layer.

E. the only dental materials that exhibit spontaneous adhesion to dentin without the necessity of preparing tooth structure are flowable composite resin materials.

Question nr 46

Which of the following **is not** an advantage of working with an operative (endodontic) microscope?

A. optimization of endodontic treatment.

B. ergonomics.

C. increased treatment time.

D. procedure saving purposes.

E. didactic goals.

Question nr 47

Which of the following microorganisms is most commonly detected in root canal-retreated teeth?

A. anaerobic Gram-positive coccus *E. faecalis*.

B. facultative Gram-negative bacteria *E. faecalis*.

C. facultative Gram-positive bacteria *Str. mutans*.

D. anaerobic Gram-negative coccus *Str. mutans*.

E. facultative Gram-positive bacteria *Actinomyces*.

Question nr 48

The maximum acceptable distance between the end of the working length and the tip of the master apical cone in the method of lateral condensation technique, is:

A. 0.5-1 mm.

- B. 1-2 mm.
- C. 2-3 mm.
- D. 4-5 mm.
- E. this factor is not important.

Question nr 49

Which of the following allow to categorize a patient into the high caries risk group?

- 1) reduced salivary flow rate;
- 2) high number of restorations;
- 3) low level of *Actinomyces*;
- 4) presence of orthodontic brackets;
- 5) high buffer capacity of the saliva;
- 6) high counts of mutans streptococci (MS) in the saliva;
- 7) healthy posterior teeth.

The correct answer is:

- A. 1,2,3,4.
- B. 4,5,6,7.
- C. 1,3,5,7.
- D. 2,4,6,7.
- E. 1,2,4,6.

Question nr 50

During the insertion of bleaching material into the tooth after root canal treatment the gingiva, for protection, should be coated with:

- A. zinc oxide.
- B. gum arabic.
- C. flowable composite.
- D. petroleum jelly.
- E. methylene blue.

Question nr 51

In a patient with high caries risk a bite-wing x-ray picture revealed the presence of a carious lesion. It was located on the mesial contact surface in tooth 36 and slightly extended below the dentin-enamel junction. What kind of procedure is indicated in this tooth?

- A. dietary and hygienic instructions, fluoride varnish application.
- B. fissure sealing.
- C. extended fissure sealing.
- D. preventive resin restoration.
- E. preparation and filling application.

Question nr **52**

A 40-year-old patient suffers from a pain on the left side. The patient is unable to identify any particular tooth/teeth as a source of the pain. An important diagnostic clue is that the pain is clearly radiating to the neck region. What group of teeth would you suspect as a cause of the symptoms?

- A. maxillary molars.
- B. maxillary premolars.
- C. mandibular molars.
- D. anterior teeth.
- E. pain radiating to the neck on the left side cannot be related to the teeth.

Question nr **53**

Which of the following statements concerning intrapulpal anesthesia is **false**?

- A. its effect lasts for a longer period of time.
- B. it is performed after access preparation and pulp chamber trephination.
- C. patients feel pain during needle insertion.
- D. anesthetic effect occurs rapidly.
- E. needle should be placed in the root canal in such a way that the

anesthetic solution cannot escape from the root canal.

Question nr **54**

Which of the following **is not** observed in the inflammatory process which develops as primary periodontal disease with secondary endodontic involvement (endo-perio)?

- A. wide pocket with dental plaque and calculus accumulation.
- B. marginal gingivitis.
- C. healthy pulp without symptoms of inflammation or necrosis.
- D. increased number of neutrophils infiltrating gingival tissues.
- E. angular bone loss around one or several teeth on X-ray.

Question nr **55**

Indicate the true statements concerning the etching of dentin prior to the application of composite material:

- 1) etching fosters the removal of the smear layer from the lumen of dentinal tubules;
- 2) etching does not cause demineralization of perinatal dentin because this dentin is more mineralized than intraoperative dentin;
- 3) prolonged etching of dentine does not improve the quality of the hybrid layer;
- 4) the use of the VII generation self-etching system is not recommended with chemically cured composite material;
- 5) penetration of resin tags into exposed dentinal tubules is crucial for the adhesion of composite materials.

The correct answer is:

- A. 1,2,3.
- B. 2,3,4.
- C. 3,4,5.
- D. 1,3,4.
- E. 1,2,5.

Question nr **56**

Indicate the proper ways of gaining access to a caries lesion on the

approximal surface of a posterior tooth:

- 1) via buccal or lingual surface when the contact point is destroyed and the caries extends towards the gingival end, leaving a sound marginal ridge;
- 2) from the occlusal surface, leaving the marginal ridge intact;
- 3) through removing the marginal ridge when the lesion is large;
- 4) through direct access if the adjacent tooth has been extracted.

The correct answer is:

- A.** 1,2,4.
- B.** 1,3,4.
- C.** 1,2,3.
- D.** 2,3,4.
- E.** all the above.

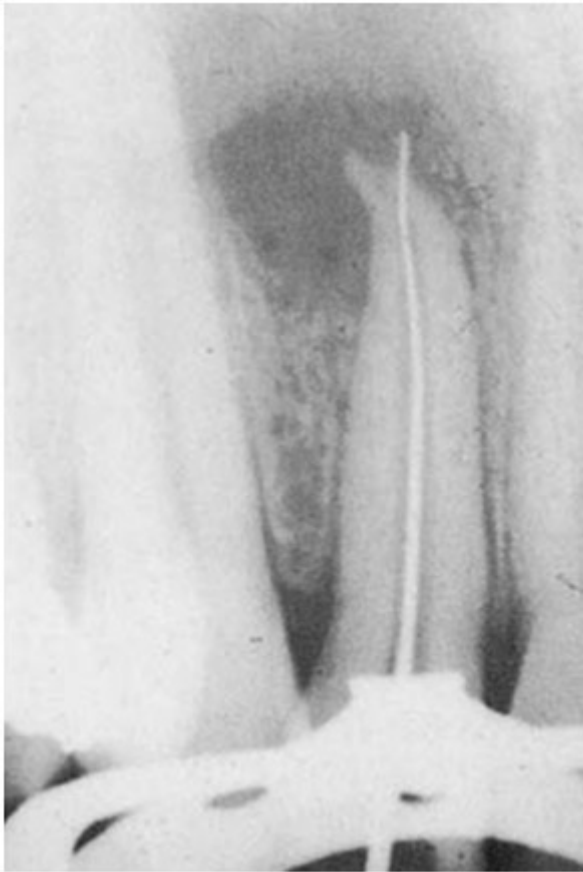Question nr 57

Indicate the diet which can be regarded as a high risk factor for caries according to Kidd:

- A.** gluten free diet.
- B.** carbohydrates rich diet.
- C.** protein rich diet.
- D.** vegetarian diet.
- E.** high-fiber diet.

Question nr 58

Which clinical situation does the following X-ray show?



- A. performing recapitulation.
- B. extrusion of gutta-percha cone beyond the apical constriction.
- C. checking patency of the root canal after correct orifice preparation.
- D. insertion of a too narrow endodontic file into the root canal during its preparation.
- E. creation of an apical perforation during endodontic treatment.

Question nr **59**

A 35-year-old patient complains of pain to mastication on teeth 15 and 16. Percussion test is positive (patient reacts with pain). Clinical and radiological examinations reveal no carious cavities or previous restorations placed in these teeth. The periapical area and periodontal status are within normal limits. The reaction on cold showed slightly increased sensitivity. What should be the next step in clinical proceeding?

- A. observation only.
- B. neurological consultation.
- C. diagnostics directed at maxillary sinusitis.
- D. endodontic treatment.

E. dentin hypersensitivity treatment.

Question nr **60**

Indicate which irrigant can replace EDTA and sodium hypochlorite to remove the smear layer:

A. hydrogen peroxide.

B. citric acid.

C. chlorhexidine.

D. calcium hydroxide.

E. physiological saline.

Question nr **61**

Which of the following is the first, clinically visible sign of the carious lesion:

A. white spot lesion.

B. porous enamel.

C. subsurface enamel breakdown.

D. constriction of apatite crystals.

E. shiny lesion.

Question nr **62**

Indicate the **false** statement concerning dental erosion:

A. it is a loss of tooth hard tissues induced by chemical processes.

B. erosion on the lingual surfaces of the maxillary teeth may be caused by regurgitation of stomach acid.

C. teeth clenching and grinding initiate erosive processes in dental tissues.

D. erosion on the buccal surfaces of the teeth may be caused by acidic beverage consumption.

E. indigestion of acidic medicines, e.g. vitamin C, may cause erosion.

Question nr **63**

Indicate the true statements concerning the process of composite polymerization:

- 1) value of C-factor in class IV restoration is 1;
- 2) self-cured composites require mixing two components;
- 3) tertiary amines in self-cured composites give them a light yellow color;
- 4) polymerization shrinkage depends on the distance between the light source and the composite;
- 5) polymerization shrinkage may damage the adhesive connection between the tooth and the composite.

The correct answer is:

- A.** 1,2,3.
- B.** 2,4,5.
- C.** 1,4,5.
- D.** 2,3,5.
- E.** 1,3,5.

Question nr **64**

In which direction the cut is made in the procedure of hemisection of mandibular molars?

- A.** lingually from bifurcation.
- B.** buccally from bifurcation.
- C.** buccolingually to bifurcation.
- D.** mesiodistally to furcation.
- E.** distomesially from furcation.

Question nr **65**

Indicate the **false** statement concerning the adhesion of restorative materials to tooth tissues:

- A.** penetration of resin to etched enamel is a fundament of composite-enamel adhesion.
- B.** smear layer reduces the permeability of the dentin for bonding agents.

- C.** etching of the dentin exposes collagen fibers and provides micromechanical adhesion of resin to the dentin.
- D.** phosphoric acid in concentration over 40% should not be used for enamel etching.
- E.** the enamel contains 10-12% of water, which makes it hydrophilic.

Question nr **66**

Which of the following dietary carbohydrate substrate are biofilm bacteria capable of fermenting?

- A.** glucose.
- B.** fructose.
- C.** lactose.
- D.** maltose.
- E.** sucrose and glucose.

Question nr **67**

Which of the following can be observed in the case of a vertical root fracture?

- A.** sinus tract.
- B.** narrow, deep, isolated periodontal probing defect.
- C.** pain on mastication.
- D.** fracture visible on radiograph.
- E.** all the above.

Question nr **68**

What is the shape of the access cavity preparation for endodontic treatment in the maxillary first molar?

- A.** triangle, with the base to the buccal surface, and the apex toward the palatal surface.
- B.** triangle, with the base to the palatal surface, and the apex toward the

buccal surface.

C. triangle, with the base to the mesial surface, and the apex toward the distal surface.

D. triangle, with the base to the distal surface, and the apex toward the mesial surface.

E. oval, flattened in the mesio-distal direction.

Question nr 69

Which of the following concerning the work with Lentulo spiral drill is true?

- 1) Lentulo spiral drill is used for engine-driven root canal preparation;
- 2) Lentulo spiral drill is used for root canal obturation;
- 3) Lentulo spiral drill is inserted without rotation to the working length;
- 4) Lentulo spiral drill is inserted without rotation to the length shorter than the working length;
- 5) Lentulo spiral drill is inserted with rotation at a slow speed (300-500/min) to the working length.

The correct answer is:

A. 1,3.

B. 1,5.

C. 2,3.

D. 2,4.

E. 2,5.

Question nr 70

What is the size of filler particles in microfill composites?

A. 10-100 μm .

B. 1-10 μm .

C. 0.1-1 μm .

D. 0.01-0.04 μm .

E. 0.002 - 0.075 μm .

Question nr 71

Which of the following statements concerning polyacid-modified composite resin materials (compomers) is **false**?

- A.** they require the use of bonding systems.
- B.** fewer fluoride ions are released from compomers than from conventional glass-ionomer cements.
- C.** they exhibit better mechanical properties than conventional glass-ionomer cements.
- D.** they require a tightly sealed packaging; once the packaging is opened, their utility time is short due to their relatively high sensitivity to environmental factors.
- E.** they contain precured glass-ionomer particles which have already been treated with polyacrylic acid.

Question nr 72

A 54 year-old man was referred for a treatment of tooth 47. The patient's current condition is good. The patient is diabetic and registered for regular specialized care. Intraoral examination reveals satisfactory dental hygiene and no additional dental treatment is needed. In tooth 47 the loss of filling on the mesial surface and the exposure of gutta percha on the floor of the pulp chamber are detected. The X-ray has revealed proper root canal obturation and no changes in the periapical region. Which of the following is recommended in the described case?

- A.** RCT of tooth 47 with antibiotic prophylaxis.
- B.** disinfection of the pulp chamber and the placement of temporary filling for 2 weeks; then - in the absence of ailments - replacement of the temporary filling with a permanent one.
- C.** patient referral for extraction of tooth 47 due to systemic disease.
- D.** consultation of the treatment plan with a diabetologist.
- E.** RCT of tooth 47 without prophylactic antibiotic therapy.

Question nr 73

Which of the following statements regarding physiologic dentin sclerosis is **false**?

- A.** it is produced following physiological aging process, mainly in root dentine.
- B.** it is the effect of odontoblasts and leads to a complete closure of dentinal tubules with peritubular dentine.
- C.** under physiological conditions about 50% of the tubules become completely obliterated.
- D.** obliteration of the tubules progresses from the periphery in the direction of the pulp.
- E.** it is often observed in dentine and lies underneath the lesions of carious or non-carious origin.

Question nr **74**

In which of the cases given below the patient may feel no pain and the disorder may be found accidentally on the X-ray?

- A.** cracked tooth.
- B.** internal root resorption.
- C.** periapical abscess.
- D.** periodontal abscess.
- E.** acute apical periodontitis.

Question nr **75**

Which of the following leads to pain sensations in patients suffering from dentin hypersensitivity?

- A.** thermal stimuli.
- B.** osmotic stimuli.
- C.** chemical stimuli.
- D.** presence of patent dentinal tubules.
- E.** all the above.

Question nr **76**

Indicate the true statements concerning the smear layer:

- 1) has a uniform amorphous structure;
- 2) contains only organic debris;
- 3) its presence decreases the risk of bacterial leakage;
- 4) its presence decreases the penetration of a sealer into dental tubules.

The correct answer is:

A. 1,2.

B. 2,3.

C. 3,4.

D. 1,4.

E. 2,4.

Question nr 77

Which of the following explains the problem of dental pulp edema in pulp inflammation?

A. lack of cells taking part in the inflammatory process.

B. hard canal walls that preclude an increase in pulp volume and blood supply through a very narrow apical foramen.

C. lack of lymph vessels.

D. insufficient cellular immune response.

E. small supply in blood vessels.

Question nr 78

After professional whitening of vital teeth in a dental office there is a high probability of side effects. Which of the following side effects are most commonly observed after that procedure?

- 1) internal resorption;
- 2) cervical resorption;
- 3) teeth hypersensitivity;
- 4) gingival irritation.

The correct answer is:

A. 1,2.

B. 1,3.

C. 2,3.

D. 2,4.

E. 3,4.

Question nr 79

Which of the following compounds may cause pH increase in the oral cavity by binding hydrogen ions?

A. urea.

B. ammonia.

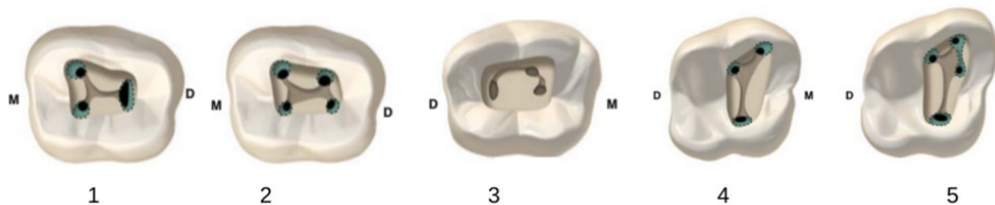
C. ammonium ion.

D. uric acid.

E. lysine.

Question nr 80

Which of the following figures shows the root canal type C and in which teeth is it most frequently found?



A. C-shaped root canal is shown in Figure 1 and is most often found in the first mandibular molars.

B. C-shaped root canal is shown in Figure 2, and is most often found in the second mandibular molars.

C. C-shaped root canal is shown in Figure 3, and is most often found in the second mandibular molars.

D. C-shaped root canal is shown in figure 4 and is most often found in the first maxillary molars.

E. C-shaped root canal is shown in Figure 5, and is most often found in the second mandibular molars.

Question nr **81**

Rotational movements may lead to the file being blocked or broken if used with:

- 1) Hedström file;
- 2) K-file;
- 3) K-reamer;
- 4) rotary NiTi instruments.

The correct answer is:

- A.** 1,2.
- B.** 2,3.
- C.** 3,4.
- D.** 1,4.
- E.** 2,4.

Question nr **82**

To obtain better apical seal of the master gutta-percha point, its apical part can be solvent-softened before placing it into the root canal. What are the indications for this method?

- A.** very narrow, obliterated root canals.
- B.** root canals with a very large apical portion.
- C.** root canals with a lateral root perforation in the coronal one-thirds of the root.
- D.** root canals with a perforation in the middle one-thirds of the root.
- E.** root canals with internal resorption.

Question nr **83**

Indicate the layer of a non-cavitated carious lesion in the enamel in which remineralization processes occur:

- A.** surface zone.
- B.** subsurface zone.
- C.** dark zone.

D. body of the lesion.

E. affected zone.

Question nr **84**

Please indicate the recommended method of final root canal obturation in the case of internal resorption:

A. single gutta-percha point method.

B. lateral compaction of gutta-percha.

C. vertical compaction of gutta-percha.

D. thermoplastic injection of gutta-percha.

E. vacuum system of obturation.

Question nr **85**

Which ions in AH26 endodontic sealer caused discoloration?

A. copper.

B. silver.

C. cadmium.

D. zinc.

E. gallium.

Question nr **86**

Remineralising fluoride preparations are an essential element for the treatment of root caries:

A. only at early stages of root caries.

B. only at advanced stages of root caries.

C. only in patients in whom no cavitation has yet occurred.

D. only in patients who live in the areas in which a fluoride concentration in drinking water is < 1 ppm.

E. at all stages of root caries.

Question nr **87**

Which of the following symptoms of irreversible pulpitis is the most reliable?

A. pain on percussion or when biting.

B. positive reaction to direct dentin stimulation test.

C. pain increasing mainly with heat and subsiding with cold stimuli.

D. increased reaction to thermal stimuli.

E. spontaneous pain.

Question nr **88**

Solubility in tissue fluids and gradual material resorption are disadvantages of the following sealants:

1) zinc oxide-eugenol based sealants;

2) sealants based on synthetic resins;

3) sealants based on natural resins;

4) sealants based on calcium dihydroxide.

The correct answer is:

A. all the above.

B. 1,2.

C. 3,4.

D. 2,3.

E. 1,4.

Question nr **89**

Indicate the true statements on the properties of citric acid used as an irrigant solution in endodontic treatment:

1) it is an alternative irrigating solution to EDTA;

2) it well dissolves inorganic remnants;

3) it has bleaching properties;

4) together with NaOCl, effectively removes the smear layer;

5) it is effective against anaerobic bacteria.

The correct answer is:

- A. 1,2,3.
- B. 3,4,5.
- C. 1,2,4,5.
- D. 1,3,4,5.
- E. all the above.

Question nr **90**

The decision on the need to implement the invasive treatment of a carious lesion is based on:

- A. lesion location.
- B. lesion activity.
- C. breaks in the enamel continuity.
- D. presence of a lesion classified as D1 acc. to WHO.
- E. age of the patient.

Question nr **91**

Which of the following statements concerning the rubber dam is **false**?

- A. light color of the rubber is preferred when restoring fillings.
- B. rubber dam clamps hold the rubber dam in position.
- C. floss ligatures may be used to hold the rubber dam in position.
- D. rubber dam protects the patients from accidental aspiration of instruments.
- E. rubber dam protects the dentist against infection from the patient.

Question nr **92**

What distance should be kept between the tip of a light-curing unit and a resin composite restoration surface to ensure effective light curing of the material?

- A. 1-2 mm.

- B.** more than 6 mm.
- C.** 1-2 cm.
- D.** recommended distance depends on the fiberoptic bundle surface.
- E.** light-curing unit distance from the surface doesn't matter.

Question nr **93**

Which of the following concerning spreaders in endodontic treatment is true?

- 1) they are used for the vertical condensation of gutta-percha;
- 2) they are used for the lateral condensation of gutta-percha;
- 3) stainless steel spreaders are used for obturation of the root canals with a significant degree of curvature;
- 4) nickel-titanium spreaders are used for obturation of the root canals with a significant degree of curvature.

The correct answer is:

- A.** 1,2.
- B.** 1,3.
- C.** 1,4.
- D.** 2,3.
- E.** 2,4.

Question nr **94**

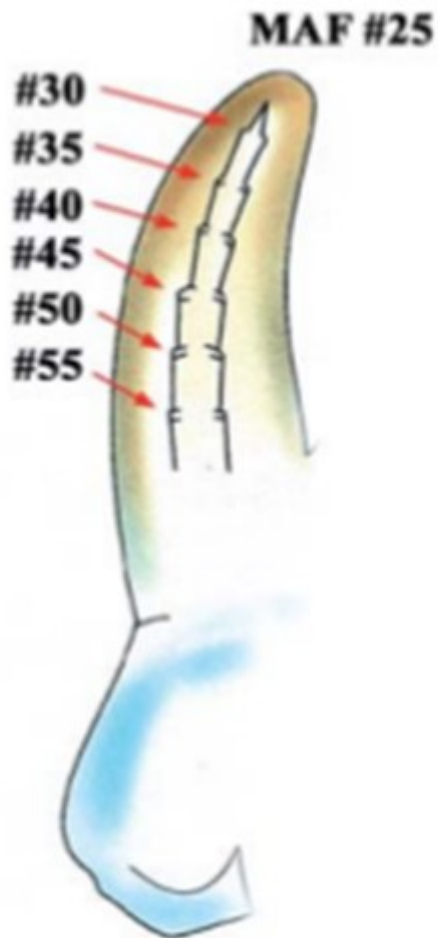
Which of the following **does not** affect the current caries risk assessment?

- A.** patient's socioeconomic status.
- B.** dental plaque.
- C.** diet.
- D.** secondary caries.
- E.** fissure sealant.

Question nr **95**

On the basis of the following description and the figure shown below indicate the method of root canal preparation: 'This method consists of widening the

apical part of the root canal to a specific size (in the figure shown below up to 25) with files inserted at the full working length. Further files are introduced into the root canal at increasingly shorter length'.



- A. balanced force technique.
- B. standardized.
- C. step-back.
- D. step-down.
- E. crown-down.

Question nr 96

Which material is the most recommended for closing a root canal perforation?

- A. Mineral Trioxide Aggregate.
- B. glass ionomer.
- C. flowable composite.
- D. composite.

E. amalgam.

Question nr 97

Which of the following symptoms may suggest a perforation?

- 1) sudden bleeding during the endodontic treatment;
- 2) sudden pain during the endodontic treatment;
- 3) abscess and bone resorption;
- 4) sinus tract and tenderness related to the endodontically treated tooth;
- 5) down-growth of a gingival epithelium tissue to the suspected perforation site;
- 6) extrusion of obturating material;
- 7) lesion healing.

The correct answer is:

- A. 1,4,6.
- B. 1,2,3,6.
- C. 3,4,5.
- D. 5,6,7.
- E. 1,2,3,4,5,6.

Question nr 98

Which of the following statements concerning Black's classification are true?

- 1) it does not cover root caries;
- 2) it does not cover secondary caries;
- 3) it does not cover non caries lesion (tooth wear);
- 4) changes in Stage 0 and Stage 1 (Sites/Stages - Si/Sta) are not included in Black's;
- 5) cervical changes in the proximal surface are qualified by Black's as class II (in lateral teeth) and class III (in anterior teeth).

The correct answer is:

- A. 1,2,3,5.
- B. 1,3,5.
- C. 2,3,4.
- D. 3,4,5.
- E. all the above.

Question nr **99**

Indicate the Si/Sta stage in Lasfargues and coworkers' classification of a carious lesion of Black's class V that extends to the enamel-dentine junction:

- A. Si/Sta 3.2.
- B. Si/Sta 3.1.
- C. Si/Sta 2.2.
- D. Si/Sta 2.1.
- E. Si/Sta 4.2.

Question nr **100**

Indicate the recommended method of determining the causative tooth responsible for a chronic apical abscess with a sinus tract:

- A. local anesthesia in the area of the sinus tract.
- B. dental tissue transillumination with a strong light source.
- C. use of Diagnodent device.
- D. taking of bitewing X-ray.
- E. x-ray image of a gutta-percha placed in the sinus tract.

Question nr **101**

Which of the following examinations should be performed during the checkup of a tooth after direct pulp capping?

- 1) examination of the marginal seal of composite material;
- 2) examination of a pulp vitality response with laser Doppler flowmetry;
- 3) evaluation of the presence of a dentin bridge on radiograph;
- 4) evaluation of the root canal widths on radiograph compared with neighbouring healthy teeth;
- 5) examination with ECM;
- 6) examination with Periotest.

The correct answer is:

- A. 1,2,3,4.
- B. 1,2,3,5.

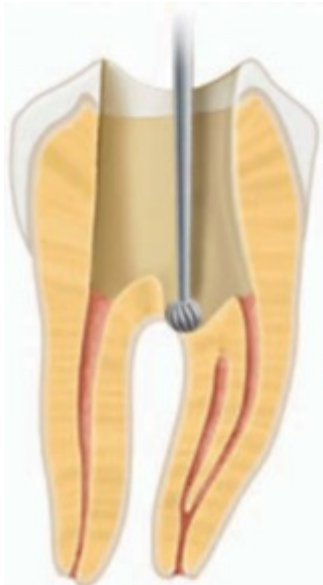C. 2,3,4,6.

D. 3,4,5,6.

E. 1,2,3,6.

Question nr **102**

What kind of treatment can you recommend in the case visible in the picture below?



- A.** finding the orifice of the third canal and performing root canal treatment.
- B.** performing root canal treatment and covering the bottom of the pulp chamber with a sealer.
- C.** performing root canal treatment and covering the bottom of the pulp chamber with $\text{Ca}(\text{OH})_2$ material.
- D.** repair of the perforation with MTA, finding the orifice of the third canal and performing root canal treatment.
- E.** tooth extraction due to the connection between the pulp chamber and periodontium.

Question nr **103**

GLUMA desensitizer is composed of:

- A.** 5% of glutaraldehyde, 35% of HEMA.
- B.** 35% of glutaraldehyde, 5% of HEMA.
- C.** 50% of glutaraldehyde, 5% of HEMA.

D. 5% of glutaraldehyde, 35% of bis-GMA.

E. 35% of glutaraldehyde, 5% of bis-GMA.

Question nr **104**

Indicate the true statements on the walking bleach technique:

- 1) this method of bleaching is used for endodontically treated teeth;
- 2) this method of bleaching is used for vital teeth with enamel defects;
- 3) this method of bleaching is used for vital teeth with dentin discolorations;
- 4) in this method concentrated hydrogen peroxide is used;
- 5) several visits are usually needed;
- 6) one visit is usually needed.

The correct answer is:

A. 1,4,6.

B. 1,3,5.

C. 1,4,5.

D. 2,3,4.

E. 2,4,6.

Question nr **105**

When performing internal bleaching with the 'walking bleach' technique, the root canal obturation material should be removed and replaced with a material that provides tight seal to the depth of approximately:

A. 0.5 mm apically from the root canal orifice.

B. 2 mm apically from the root canal orifice.

C. 4 mm apically from the root canal orifice.

D. 5 mm apically from the root canal orifice.

E. 3 mm from the apex of the tooth.

Question nr **106**

Indicate the rules for working with NiTi rotary instruments:

- 1) it's necessary to verify canal patency with a hand file;
- 2) observing the correct torque;

- 3) maintaining the constant speed of 700 rpm;
- 4) rotational movements in the range not exceeding 90°;
- 5) rinsing the root canal with each usage of the file.

The correct answer is:

- A.** 1,2,3.
- B.** 1,2,5.
- C.** 3,4,5.
- D.** 1,3,4.
- E.** 1,2,4.

Question nr **107**

Which material is the best to seal perforations occurring during access preparation for endodontic treatment?

- A.** calcium hydroxide.
- B.** amalgam.
- C.** glass ionomer cement.
- D.** MTA.
- E.** zinc oxide-eugenol cement.

Question nr **108**

What kind of rubber dam retainers are recommended when the anchor tooth is partially erupted?

- A.** retainers with prongs directed gingivally.
- B.** winged retainers.
- C.** retainers such as W2 with small jaws.
- D.** retainers with classic, non-inverted prongs.
- E.** retainers such as W7 with big jaws.

Question nr **109**

Indicate the true statements about endodontic treatment complications:

- 1) perforation is the unintentional connection between the tooth cavity and the oral environment;
- 2) incomplete pulp extirpation causes residual pulpitis;
- 3) in the case of edema, antibiotic therapy is not recommended, only the use of non-steroidal anti-inflammatory drugs;
- 4) breaking the file during root canal filling results in the necessity for tooth extraction;
- 5) overfilling of the root canal may result in the necessity for surgical treatment.

The correct answer is:

- A.** 1,2.
- B.** 2,5.
- C.** 3,4.
- D.** 3,5.
- E.** 2,4.

Question nr 110

What is the etiological factor of the external root resorption, a resorption in which a characteristic flat shortening of the root tips is observed?

- A.** pulp necrosis.
- B.** internal bleaching.
- C.** orthodontic treatment.
- D.** periodontal treatment.
- E.** hormonal disorders.

Question nr 111

The possible causes for a false negative response to an electric pulp test include:

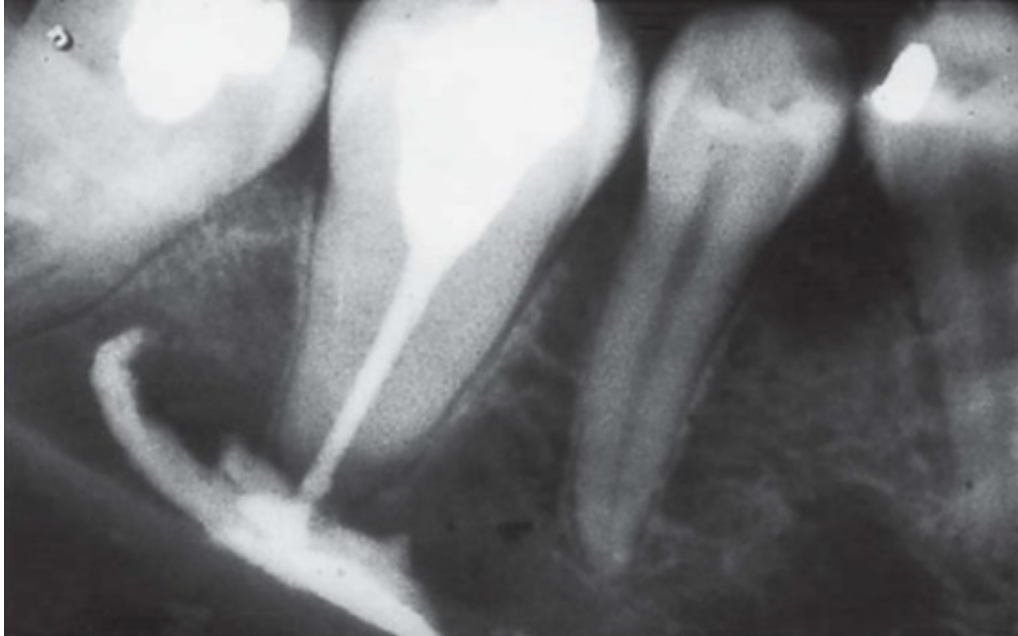- A.** tooth after traumatic shock (concussion).
- B.** calcified canals.
- C.** incomplete pulp innervations with partially developed roots (in open apex teeth).

D. local anesthesia to the examined tooth.

E. all the above.

Question nr **112**

Which symptoms may occur in the situation presented on the following radiograph?



A. headache.

B. facial nerve palsy.

C. sensory abnormalities in the area supplied by the inferior alveolar nerve.

D. temporomandibular joint disorders.

E. trigeminal nerve neuralgia.

Question nr **113**

A patient presents to the dentist with recurring pain on biting in tooth 32. The tooth was treated endodontically half a year before. The X-ray reveals the proper obturation of the root canal as well as a periapical lesion. The marginal periodontium is sound. What kind of procedure should be proposed?

A. because of recurring pain and endodontic treatment carried out not long ago - tooth monitoring, the lesion may heal spontaneously.

B. endodontic retreatment of the previously obturated canal.

C. taking an X-ray in another projection and in the case of finding not obturated root canal the endodontic retreatment with the attempt to find the second canal in the labio-lingual direction.

D. apical root resection.

E. tooth extraction because of the failure of previous endodontic treatment.

Question nr **114**

Which of the following is the most common side effect of the intracoronal bleaching of endodontically treated tooth?

A. external root apex resorption.

B. external cervical root resorption.

C. necrosis of the oral mucosa.

D. breakage of the enamel.

E. changes in the structure of the dentine and the cement.

Question nr **115**

Which of the following **is not** observed in the endodontium as a result of aging?

A. narrowing of the pulp chamber and root canals due to secondary dentin deposition.

B. pulp cell number reduction.

C. reduced pulp vascularity.

D. increase in the number of nerve fibers.

E. increased mineral deposits in dentinal tubules.

Question nr **116**

Indicate the true statement concerning secondary caries:

A. secondary caries develops along the border line of the filling and the dental tissues.

B. secondary caries most often develops on the gingival wall of the cavity.

- C.** use of cariostatic fillings eliminate the development of secondary caries.
- D.** appearance of a brown border around the filling indicates the presence of secondary caries.
- E.** any marginal leakage means the presence of active secondary caries and requires a replacement of the filling.

Question nr **117**

Generalized malaise and elevated body temperature is the most commonly associated with:

- A.** reversible pulpitis.
- B.** irreversible pulpitis.
- C.** condensing osteitis.
- D.** acute apical abscess.
- E.** chronic apical abscess.

Question nr **118**

Indicate the true statements concerning the morphology of permanent teeth:

- 1) in the mandible the central incisor is larger than the lateral incisor;
- 2) the longest tooth in the human dentition is the upper canine;
- 3) the root of the upper lateral incisor is often distally or palatally curved;
- 4) the second maxillary premolar in most cases has two root canals.

The correct answer is:

- A.** 1,2,3.
- B.** 2,3,4.
- C.** 1,4.
- D.** 2,3.
- E.** all the above.

Question nr **119**

Indicate the correct statement concerning the master apical file (MAF):

- A.** is the first file which reaches the working length.

- B. is a file 3 sizes wider than the initial file.
- C. corresponds to the minimum diameter of the root apex.
- D. it should be disposed after a single use.
- E. its diameter is 2-4 mm bigger than the end of the final file (FF).

Question nr **120**

Which of the following is affected by molar incisor hypomineralization manifested by morphological enamel defects:

- A. buccal surface of the second permanent molars and/or ½ surface of mandibular incisors.
- B. occlusal surface of the third permanent molars and all incisors.
- C. occlusal surface of the first milk molars and maxillary incisors.
- D. occlusal surface of the first permanent molars and/or incisal 1/3 of the crown of incisors.
- E. all the surfaces of the first permanent molars and maxillary central incisors are affected.

Question nr **121**

Which would be the treatment of choice for tooth 24 covered with a crown, with an overfilling of obturation material, signs of apex resorption and positive reaction on percussion?

- A. apicoectomy.
- B. extraction.
- C. observation.
- D. RCT.
- E. laser biostimulation.

Question nr **122**

Indicate the **false** statement concerning the use of chlorhexidine mouthrinses in caries prophylaxis:

- A. they are recommended in patients from the moderate caries risk group.
- B. recommended period of use of the mouthrinse is about 2 weeks.
- C. effect of their usage is a decrease in *Streptococcus mutans* titer in the mouth.
- D. concentration of chlorhexidine does not exceed 0.2%.
- E. they are recommended in patients from the high caries risk group.

Question nr **123**

Which cells are involved in the generation of reparative dentine?

- A. fibroblasts only.
- B. odontoblasts only.
- C. at first odontoblasts, then fibroblasts.
- D. at first fibroblasts, then odontoblasts.
- E. ameloblasts and odontoblasts.

Question nr **124**

Mixing calcium hydroxide with physiological saline to form a paste and then applying it to the exposed pulp in a sterile environment results in:

- 1) a mild inflammatory reaction of tissues lying underneath the ones being in contact with the paste;
- 2) at first the necrosis of the pulp tissues contacting the paste and then the healing into a fully formed, healthy vital pulp;
- 3) necrosis of the pulp tissues contacting the paste, then a demarcation zone rich in collagen forms, and eventually a mineralized barrier;
- 4) eventually a mineralized barrier called the dentin bridge;
- 5) either general acute pulpitis or necrosis.

The correct answer is:

- A. 1,2.
- B. 1,3,4.
- C. 2,5.
- D. 3,4,5.

E. 1,4,5.

Question nr 125

What is the pH of EDTA irrigation fluid used in endodontics?

A. 2.

B. 4.

C. 7.

D. 9.

E. 14.

Question nr 126

Sharp, severe pain occurring in the restored tooth on biting, especially while releasing the bite, and after cold stimuli may indicate:

A. pulpitis.

B. acute periodontitis.

C. chronic periodontitis.

D. cusp fracture.

E. poor occlusal adjustment of the restoration.

Question nr 127

Resin-modified glass-ionomers (RMGI), compared with conventional glass-ionomers:

A. can be used only as liners.

B. can be contoured and polished just after polymerization.

C. polymerize in a way in which acid-base reactions do not occur.

D. have worse physical properties.

E. release fewer fluoride ions.

Question nr 128

Which complication is the most commonly observed after internal bleaching?

- A.** secondary caries.
- B.** cervical external root resorption.
- C.** cervical enamel demineralization.
- D.** inflammatory apical root resorption.
- E.** ulcerative-necrotizing gingivitis.

Question nr **129**

According to ICDAS II classification the code 3 means:

- A.** change visible in the wet enamel.
- B.** cavity in the enamel without visible dentine.
- C.** carious lesion in the dentin, without a cavity in the enamel.
- D.** carious lesion in the dentin with a cavity in the enamel.
- E.** distinct cavity with visible dentine.

Question nr **130**

What are the disadvantages of intrapulpal anesthesia?

- 1) short duration of the anesthesia;
- 2) exquisitely painful application;
- 3) anesthesia should be given under high pressure;
- 4) possibility of periodontal soft tissue oedema.

The correct answer is:

- A.** all the above.
- B.** 1,2,3.
- C.** 1,2.
- D.** 2,3.
- E.** 1,3.

Question nr **131**

Indicate the recommended way to remove the rubber dam which was placed

as a multiple-tooth application:

- A.** remove the clamp with forceps and remove it together with the rubber from the mouth.
- B.** remove the clamp and next remove the rubber from the mouth.
- C.** stretch the dam away from the teeth and cut it with scissors.
- D.** place the lubricant on the rubber to easily remove it from the teeth.
- E.** there is no special recommendation how to remove the rubber dam.

Question nr **132**

Indicate the **false** statement concerning apexogenesis:

- A.** apexogenesis can be performed only when the pulp of the tooth is vital.
- B.** pulpotomy is usually performed to remove the infected pulp in a tooth with immature root.
- C.** MTA is a material that can be used to stimulate apexogenesis.
- D.** apexogenesis can be performed in primary and secondary teeth.
- E.** the time required for apexogenesis ranges between 1 and 2 years.

Question nr **133**

In order to avoid operational complications while performing instrumentation of curved canals, there is a need to follow certain rules which include:

- A.** prior to the instrumentation of the apex, one should eliminate the cervical curvature.
- B.** steel instruments may be precurved, or one can use flexible Ni-Ti files.
- C.** in difficult areas rotary instruments with 6% taper should be used.
- D.** correct answer is A,B.
- E.** correct answer is A,B,C.

Question nr **134**

Indicate the true statements concerning glass-ionomer cements:

- 1) glass-ionomer cements show micromechanical and chemical adhesion;

- 2) resin modified glass-ionomer restorative materials can be finally finished immediately after light curing;
- 3) conventional glass-ionomer materials release more fluoride than resin modified glass-ionomer;
- 4) addition of tartaric acid to conventional glass-ionomers increases fluoride release;
- 5) compomer is another name for the resin modified glass-ionomer material.
- The correct answer is:

- A.** 1,2,3.
- B.** 2,4,5.
- C.** 1,4,5.
- D.** 2,3,5.
- E.** 1,3,5.

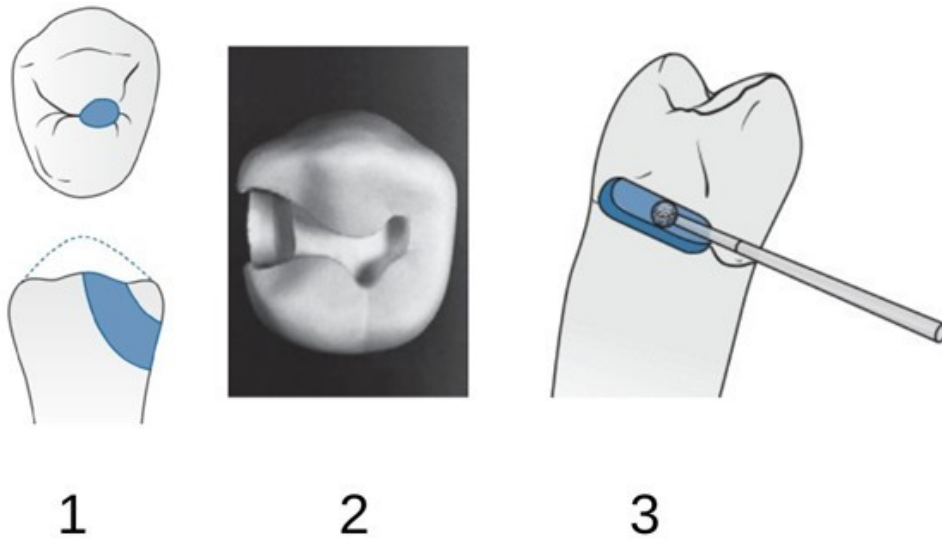
Question nr **135**

Which of the following statements concerning tooth wear is **incorrect**?

- A.** etiology of tooth wear is multifactorial.
- B.** as opposed to caries, a direct loss of tooth substance is observed without the stage of subsurface demineralization.
- C.** tooth wear is always a pathological process.
- D.** both endogenous and exogenous factors contribute to tooth wear.
- E.** symptoms of tooth wear should be periodically monitored by the dentist.

Question nr **136**

What are the names of the following types of cavity preparation in the premolar?



- A.** 1 - slot preparation, 2 - tunnel preparation, 3 - PRR method.
- B.** 1 - tunnel preparation, 2 - traditional preparation of Black's class II cavity, 3 - slot preparation.
- C.** 1 - tunnel preparation, 2 - PRR method, 3 - traditional preparation of Black's class II cavity.
- D.** 1 - slot preparation, 2 - traditional preparation of Black's class II cavity, 3 - tunnel preparation.
- E.** 1 - PRR method, 2 - traditional preparation of Black's class II cavity, 3 - tunnel preparation.

Question nr **137**

Indicate the true information concerning dead tracts observed in tooth tissues:

- 1) dead tracts appear in enamel;
- 2) dead tracts appear in dentin;
- 3) these are pores in the sub-surface, demineralized enamel layer;
- 4) these are empty dentinal tubules;
- 5) they are formed by odontoblast-like cells differentiated from mesenchymal cells of the pulp.

The correct answer is:

- A.** 1,4.
- B.** 1,5.
- C.** 2,3.

D. 2,4.

E. 2,5.

Question nr **138**

Indicate the true statement concerning the mechanism of fluorosis development:

A. fluor affects the function of ameloblasts only in the secretory phase.

B. the first two years of life are the greatest risk of enamel fluorosis in deciduous incisors.

C. repeatedly taken low doses of fluoride do not cause fluorosis.

D. fluoride-rich diet is not a risk of fluorosis.

E. excess of fluoride adversely affects the size, quantity, shape and quality of enamel apatites.

Question nr **139**

Which phenomena are observed in overdried dentin after etching?

1) collapse of collagen fibers;

2) emulsification;

3) increased impregnation of collagen fibers with a hydrophilic primer;

4) limitation of monomer penetration into the channels formed after the dissolution of hydroxyapatite crystals;

5) decrease in adhesion force.

The correct answer is:

A. 1,2,3.

B. 2,3,4.

C. 1,4,5.

D. 3,4,5.

E. 1,2,5.

Question nr **140**

How long does the dental plaque remain acid until it returns to its normal pH value 7?

- A. for 5-10 minutes.
- B. for 10-15 minutes.
- C. for 15-30 minutes.
- D. for 30-60 minutes.
- E. longer than 60 minutes.

Question nr **141**

Indicate the true statements regarding sodium hypochlorite (NaOCl):

- 1) NaOCl can be used during endodontic treatment in a concentration of 0.5-5.25%;
- 2) heating NaOCl results in its lower efficiency;
- 3) NaOCl dissolves necrotic and living organic tissue;
- 4) NaOCl does not show any antibacterial activity.

The correct answer is:

- A. 1,2.
- B. 1,3.
- C. 2,4.
- D. 2,3.
- E. 3,4.

Question nr **142**

The root canal obturation based on the application of warm gutta-percha through various techniques is characterized by:

- 1) possibility of pushing the material beyond the apical foramen;
- 2) gutta-percha shrinkage after cooling;
- 3) lack of the filling of lateral canals;
- 4) necessity to use a sealer;
- 5) harmful effect of thermoplasticized gutta-percha on the periradicular tissues.

The correct answer is:

- A. 1,2,3.
- B. 1,2,4.
- C. 2,3,4.

D. 1,2,5.

E. 1,3,5.

Question nr **143**

The first mandibular molar most commonly has:

A. 2 roots and 2 canals.

B. 2 roots and 3 canals.

C. 2 roots and 4 canals.

D. 3 roots and 3 canals.

E. 3 roots and 4 canals.

Question nr **144**

What is the preferred concentration of chlorhexidine used for root canal treatment?

A. 0.2%.

B. 0.5%.

C. 2%.

D. 20%.

E. 40%.

Question nr **145**

Cold lateral condensation of cold gutta-percha can be terminated when:

A. accessory gutta-percha point bends when entering the canal.

B. accessory gutta percha point do not enter the canal deeper than 3-5 mm.

C. sealant flows out of the canal orifice.

D. the spreader cannot enter the canal deeper than $\frac{1}{2}$ of the working length.

E. it is not possible to rotate the spreader in the canal.

Question nr **146**

The term 'preventive restoration' may include the following procedures:

- 1) fisurotomy;
- 2) enamel infiltration;
- 3) enameloplasty;
- 4) minimal invasive preparation on the labial surface;
- 5) fissure sealant application;
- 6) tunnel preparation.

The correct answer is:

- A.** 1,2,3.
- B.** 2,3,4.
- C.** 1,5,6.
- D.** 2,4,6.
- E.** 1,3,5.

Question nr **147**

Which of the following factors may have a negative effect on the prognosis of endodontic treatment?

- A.** presence of facultative anaerobes such as *Enterococcus faecalis* in the root canal.
- B.** presence of fungi in the endodontic biofilm.
- C.** presence of black pigmented bacteria such as *Prevotella nigrescens* in the root canal.
- D.** presence of an extensive periodontal lesion.
- E.** all of the above.

Question nr **148**

Indicate the true statement concerning denticles (pulp stones):

- A.** they always occur in close proximity to arterioles.
- B.** they are tiny calcifications with typical tubular dentin structure.
- C.** there are 3 types of denticles recognized by their location: free,

embedded and adherent stones.

D. all denticles are attached to the dentin of the pulp chamber.

E. they occur in healthy pulp only.

Question nr **149**

Hemisection consists in the separation and removal of:

A. root only.

B. root with the adequate part of the crown.

C. part of the crown only.

D. apical area of the root.

E. none of above.

Question nr **150**

Which of the substances when combined with calcium hydroxide, which is used as intracanal dressing, enhances its antimicrobial activity?

A. saline solution.

B. glycerin.

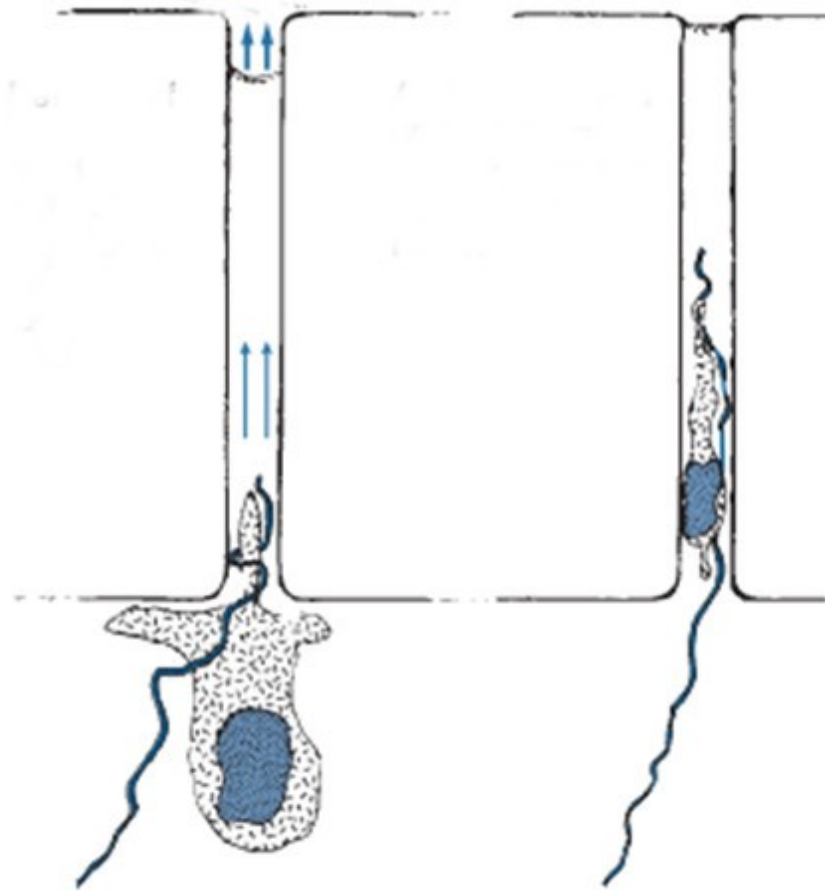
C. 2% lignocaine.

D. 2% metronidazol.

E. 2% chlorhexidine.

Question nr **151**

The figure below shows the odontoblast cell aspirated into the dentinal tubule. In what situation such a complication can take place?



- A. too long washing of the medium cavity.
- B. too long washing of the deep cavity.
- C. deep cavity drying with a sterile swab.
- D. deep cavity drying with a strong stream of air.
- E. drying of a healthy tooth enamel surface with a strong stream of air.

Question nr **152**

Which will be the most effective agent in bleaching patient's teeth discolored grey because of tetracycline intake during childhood?

- A. 2% hydrogen peroxide.
- B. 1% sodium perborate.
- C. 15% carbamide peroxide.
- D. 11% silicon carbide.

E. 5% urea peroxide.

Question nr **153**

Which of the following symptoms **is not** observed in patients with reduced salivary flow?

A. decreased thickness of the saliva.

B. altered taste sensation.

C. increased susceptibility of the oral mucosa to traumatic ulceration and infections.

D. increased teeth sensitivity to thermal stimuli.

E. rampant caries.

Question nr **154**

Which epidemiological index is characterized by DMFT index?

A. increase in caries prevalence.

B. effectiveness of caries treatment.

C. highest caries values in population.

D. dental caries prevalence.

E. rate of caries development.

Question nr **155**

Which of the following is an example of an **improper** usage of wooden wedges?

A. securing the rubber dam instead of the clamp.

B. supporting the matrix band.

C. slight dislocation of the teeth.

D. inversion of the rubber dam.

E. protection of the gums against an injury.

Question nr **156**

During root canal irrigation at the tooth 11 with sodium hypochlorite in a 33-year-old patient a sudden swelling of the subnasal region appeared, accompanied by a severe pain which prevented the continuation of the treatment on the day of the visit. What are the ways of avoiding such situations?

- 1) insert the needle maximally to half of the root canal length;
- 2) ensure the outflow of the applied irrigant from the canal;
- 3) adjust the needle diameter to the diameter of the root canal so that the needle closes tightly the lumen of the root canal;
- 4) slowly administer the irrigating solution into the root canal;
- 5) during irrigation procedure use endodontic needles with a lateral opening.

The correct answer is:

- A.** 1,2,3.
- B.** 1,2,4.
- C.** 1,3,5.
- D.** 2,4,5.
- E.** 3,4,5.

Question nr **157**

A patient comes to the dental office for the radiological control of the tooth previously treated endodontically and filled with the method of lateral gutta-percha compaction with an epoxy resin sealer. The X-ray image revealed the enlargement of the periapical lesion at the root of the tooth with inadequate root canal filling. Indicate the correct management in this case:

- A.** observation and another radiological control in 3-4 months.
- B.** retreatment of the previously treated root canal with 2% chlorhexidine to remove the filling material from the canal.
- C.** retreatment of the previously treated root canal with Lentulo drill to remove the filling material from the canal.
- D.** retreatment of the previously treated root canal with heated Hedström file to remove the filling material from the canal.
- E.** resection of the tooth root.

Question nr **158**

The technique of root canal preparation based on a 90°-180° clockwise rotation of the instrument and then a 120°-180° counterclockwise rotation is called:

- A. anticurvature filing technique.
- B. circumferential filing technique.
- C. reaming technique.
- D. filing technique.
- E. balanced force technique.

Question nr **159**

Which of the statements regarding chlorhexidine are true?

- 1) it has strong bacteriostatic, bactericidal and antifungal properties;
- 2) it electrostatically binds to the surface of bacteria, causes a leakage of intracellular substance and consequently causes cell death;
- 3) it binds with hydroxyapatite and by changing its properties prevents the attachment of bacteria;
- 4) its 2% solution used in endodontic treatment effectively eliminates *E. faecalis*.

The correct answer is:

- A. all the above.
- B. 2,3,4.
- C. 1,3,4.
- D. 1,2,4.
- E. 1,2,3.

Question nr **160**

Indicate the correct sequence rubber dam placing:

- 1) marking places for cutting holes in the rubber;
- 2) putting the rubber on the holder;
- 3) checking whether the clamp has good stabilization on the treated tooth;
- 4) choosing the correct clamp;
- 5) attaching the dental floss to the clamp wings;
- 6) pulling the rubber beneath the contact points of the treated tooth.

The correct answer is:

A. 1,2,3,5,6,4.

B. 4,5,3,6,2,1.

C. 4,1,5,3,2,6.

D. 2,1,5,4,3,6.

E. 3,1,2,5,4,6.

Question nr **161**

Indicate the **false** statement concerning root caries:

A. it often develops on exposed root surfaces.

B. cementum is rougher than enamel, which facilitates plaque deposition.

C. bacteria of *Streptococcus mutans* strain participate in the development of root caries.

D. bacteria of *Actinomyces sp.* participate in the development of root caries.

E. root caries progresses slower than smooth surface caries on the crown of the tooth.

Question nr **162**

Which of the following are the disadvantages of sealers with a zinc-oxide-eugenol base?

1) solubility;

2) homogenous consistency;

3) easy application;

4) no control in regard to postoperative symptoms;

5) cytotoxicity;

6) antibacterial effect.

The correct answer is:

A. 1,4.

B. 1,5.

C. 4,5.

D. 2,6.

E. 2,3.

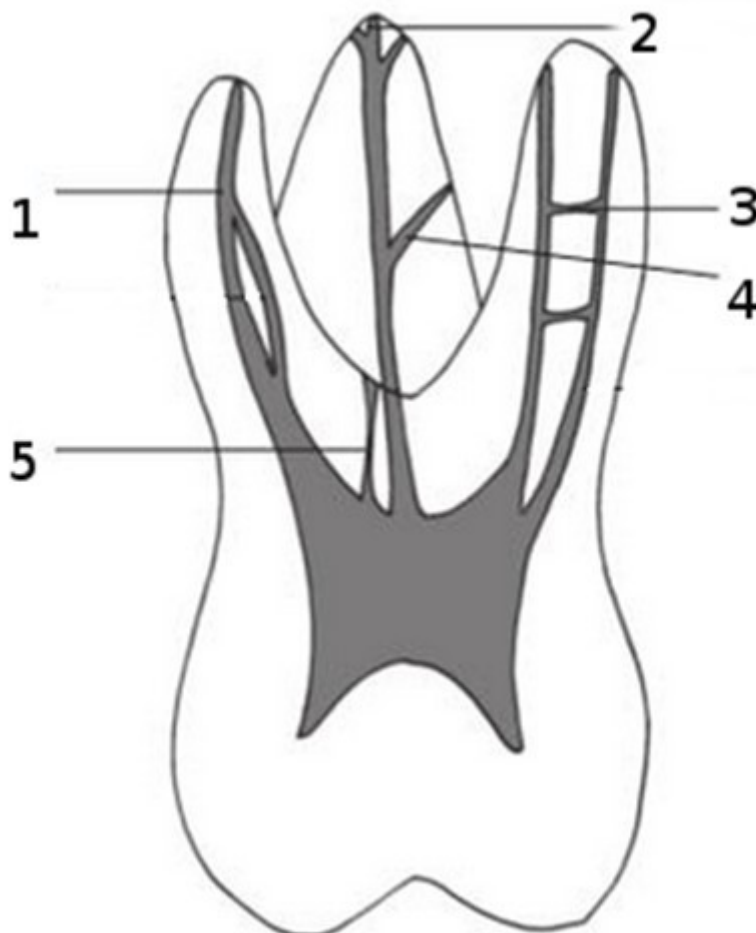
Question nr **163**

Indicate **the false** statement concerning inorganic ingredients of saliva?

- A. amount of sodium ions is low in unstimulated saliva and increases in stimulated saliva.
- B. amount of HCO_3^- increases in unstimulated saliva and decreases in stimulated saliva.
- C. Ca^{2+} ions appear in saliva in the same form as in apatite.
- D. inorganic components are present in saliva in the ionic form.
- E. the bicarbonate ions present in saliva do not come from the blood.

Question nr **164**

From the mentioned below indicate the terms corresponding to the structures marked in the figure:



- A. 1-main canal, 2-apical delta, 3-anastomosis, 4-lateral canal, 5-furcation

canal.

B. 1-main canal, 2-anastomosis, 3-apical delta, 4-lateral canal, 5-furcation canal.

C. 1-lateral canal, 2-main canal, 3-anastomosis, 4-accessory canal, 5-apical delta.

D. 1-anastomosis, 2-main canal, 3-apical delta, 4-lateral canal, 5-furcation canal.

E. 1-lateral canal, 2- anastomosis, 3-apical delta, 4-accessory canal, 5-main canal.

Question nr **165**

Which intracanal disinfecting medicaments may alleviate postoperative pain?

A. chlorhexidine.

B. Ca(OH)₂.

C. glucocorticosteroids.

D. phenols.

E. aldehydes.

Question nr **166**

In which of the following cases may the indirect pulp capping procedure be performed?

A. tooth has increased and prolonged response to ethyl chloride.

B. tooth is painful on percussion test.

C. the carious lesion is not completely removed.

D. accidental pulp exposure occurs.

E. the patient complains of spontaneous tooth pain.

Question nr **167**

Which of the following is **the least** probable cause of external resorption?

- A. orthodontic treatment.
- B. long-standing chronic inflammation of the periapical tissues.
- C. internal teeth bleaching.
- D. arrested caries.
- E. tooth luxation.

Question nr **168**

A 28-year-old man came to the dental office reporting a sharp pain in tooth 34 occurring on eating, especially ice-cream. On intraoral examination an abrasion was found in tooth 34 at the cervical area on the buccal surface. It was observed that cold stimulation caused intense pain which disappeared quickly after a cessation of the stimulus. No reaction on percussion was noticed. What is the correct diagnosis in this case?

- A. reversible pulpitis.
- B. irreversible pulpitis.
- C. acute apical periodontitis.
- D. chronic apical periodontitis.
- E. apical abscess.

Question nr **169**

The advantages of NaOCl include:

- A. effective flushing out debris from the canal.
- B. ability to dissolve necrotic tissues.
- C. antimicrobial action.
- D. bleaching action.
- E. all of the above.

Question nr **170**

Indicate the consequences of a prolonged drying of the cavity with compressed air:

- 1) decreasing the binding strength of the bonding system;
- 2) positive impact on the formation of the hybrid layer;
- 3) displacement of odontoblasts deeper into the pulp;
- 4) collapse of exposed collagen fibers.

The correct answer is:

- A. 1,2.
- B. 1,4.
- C. 2,3.
- D. 2,4.
- E. 3,4.

Question nr 171

In which of the following clinical situations is fissure sealant **contraindicated**?

- A. incipient caries.
- B. deep, retentive fissures in the tooth.
- C. interproximal cavitated caries in the tooth.
- D. high caries risk.
- E. healthy tooth, just after eruption.

Question nr 172

Fluoride ions influence cell metabolism of *Streptococcus mutans* through the following mechanisms, **except for**:

- A. inhibition of extracellular polysaccharide formation.
- B. inhibition of intracellular polysaccharide formation.
- C. inhibition of enzyme activity inside bacterial cells.
- D. inhibition of bacterial adhesion to the dental plaque.
- E. increasing the amount of storage carbohydrates.

Question nr 173

Indicate the true statements regarding 2% chlorhexidine used in endodontics:

- 1) can be used as an alternative to sodium hypochlorite;
- 2) binds to the positively charged cytoplasmic membrane of bacterial cells;
- 3) is neutralized in the root canal in the presence of organic tissue;
- 4) has antifungal properties;
- 5) has the ability to bind to hydroxyapatite.

The correct answer is:

- A.** 1,2,5.
- B.** 2,3,4.
- C.** 3,4,5.
- D.** 1,2,4.
- E.** 1,3,5.

Question nr 174

Which of the following methods is recommended for treating the vertical root fracture?

- 1) MTA application to the fracture site;
- 2) closure of the fracture site with glass-ionomer;
- 3) adhesive luting of the fractured parts;
- 4) orthodontic extrusion in order to visualize the fracture line and apply a biocompatible material;
- 5) tooth extraction.

The correct answer is:

- A.** 1,5.
- B.** 1,2,5.
- C.** 1,3,5.
- D.** 1,4,5.
- E.** only 5.

Question nr 175

Indicate the true statement concerning avulsions:

- A.** it is very important to keep the tooth in some moisture e.g. saliva.

- B.** replantation should be performed not later than 1 hour after trauma.
- C.** if the tooth is kept in the suitable storage medium the periodontal ligament has a good chance to remain vital.
- D.** if trauma occurs in an immature tooth with a wide-open apex then there is a chance of re-vascularization and proper apex formation after replantation.
- E.** all the above.

Question nr **176**

Indicate the root canal instrument characterized by the following description: 'it is a hand, stainless steel, disposable instrument, it is manufactured from round wires, and its smooth surface is notched to form spiral spikes; the tool should be used carefully as it can get stuck in the canal and break':

- A.** K File.
- B.** finger spreader.
- C.** Gates Glidden drill.
- D.** Lentulo spiral filler.
- E.** barbed broach.

Question nr **177**

After consumption of cariogenic food, the plaque pH returns to its neutral values within approximately:

- A.** 15-30 minutes.
- B.** 30-60 minutes.
- C.** 60-90 minutes.
- D.** 90-120 minutes.
- E.** pH returns to its neutral values immediately.

Question nr **178**

Indicate the **false** statement concerning intrapulpal anesthesia:

- A.** the pulp must be exposed to permit direct injection.

- B.** intrapulpal injection can be performed on single-rooted teeth only.
- C.** intrapulpal injection is very painful.
- D.** no special syringes or needles are required to perform intrapulpal injection.
- E.** duration of this type of anesthesia is very short.

Question nr **179**

Which of the following is associated with root-surface caries?

- 1) *Streptococcus mutans*;
- 2) *Lactobacillus acidophilus*;
- 3) Gram-positive *Actinomyces spp.*;
- 4) Gram-negative *Actinomyces spp.*

The correct answer is:

- A.** 1,3.
- B.** 1,4.
- C.** 1,2,3.
- D.** 1,2,4.
- E.** all the above.

Question nr **180**

The finishing of resin-modified glass-ionomer restorations is performed:

- A.** at the same appointment at which the restoration was placed.
- B.** 24 hours the after restoration placement.
- C.** 24-72 hours the after restoration placement.
- D.** after the material is placed into the cavity, and before it is light-cured.
- E.** after RMGI is placed, the patient is asked to bite on it, so that there is no need to finish or adjust the restoration.

Question nr **181**

Which of the following restorations undergoes creep as a result of cyclical occlusal stress?

- A. nano-filled composites.
- B. hybrid composites.
- C. amalgams.
- D. flowable composites.
- E. compomers.

Question nr **182**

In order to prepare MTA for use appropriately, the powder should be mixed with:

- A. lime water at 2:1 ratio.
- B. distilled water at 1:1 ratio.
- C. lime water at 1:1 ratio.
- D. silver nitrate at 1.5:1 ratio.
- E. distilled water at 3:1 ratio.

Question nr **183**

Indicate the true statements concerning root canal irrigation:

- 1) it is recommended to irrigate the canal after applying each file;
- 2) use of endodontic needles increases safety, but significantly reduces the effectiveness of irrigation;
- 3) optimal rinsing effect is obtained after inserting the needle to 1/3 of the working length of the root canal;
- 4) irrigants used in endodontics quickly deactivate;
- 5) effective cleaning of the apical part of a root canal is obtained, when an irrigant is used in the canal prepared up to ISO 25.

The correct answer is:

- A. 1,4.
- B. 2,3.
- C. 1,2.
- D. 3,5.

E. 4,5.

Question nr 184

A 42-year-old man came to the dental office complaining of severe throbbing pain of tooth 25. On examination: the pain on percussion and a prolonged reaction to cold were observed. What kind of treatment should be performed?

- A.** observation for 3 days.
- B.** oral antibiotic therapy.
- C.** partial caries preparation and ZOE placement.
- D.** pulpotomy and calcium hydroxide dressing placement.
- E.** extirpation and chemomechanical root canal preparation.

Question nr 185

What are the recommended concentrations of sodium fluoride in mouthrinses for daily use (1) and for the use under professional control (2)?

- A.** 1: 0.02%; 2: 0.05%.
- B.** 1: 0.02%; 2: 0.10%.
- C.** 1: 0.05%; 2: 0.10%.
- D.** 1: 0.05%; 2: 0.20%.
- E.** 1: 0.20%; 2: 0.50%.

Question nr 186

Which of the following clinical tests is the most reliable in assessing the status of the pulp?

- A.** electrical.
- B.** cold.
- C.** dentin stimulation (cavity test).
- D.** heat.
- E.** percussion.

Question nr 187

Indicate the true statements regarding cold gutta-percha lateral compaction:

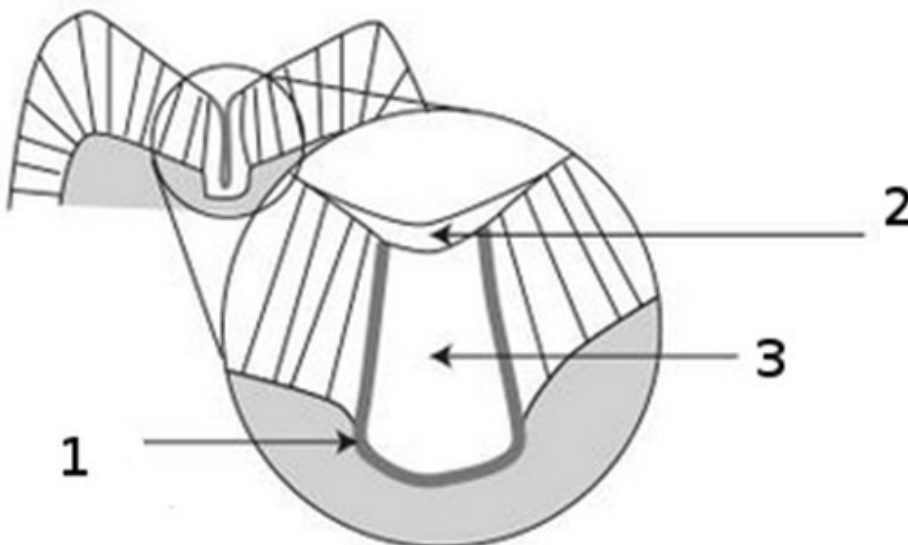
- 1) master cone should fit in the apical portion of the canal, there should be a noticeable resistance upon its removing;
- 2) accessory cones are placed in the canal at the same length as the master cone;
- 3) spreader should be inserted into the canal for a longer length than the defined working length;
- 4) immediately after removing the spreader, the earlier prepared accessory cone should be placed into the canal.

The correct answer is:

- A. 1,2.
- B. 2,3.
- C. 1,4.
- D. 1,3.
- E. 2,4.

Question nr 188

In the figure the scheme of preventive resin restoration is shown. Assign the numbers marked in the figure to the materials that are used in this procedure:



- A. 1-liner, 2-amalgam, 3-composite.
- B. 1-base, 2-bond used in rebonding procedure, 3-composite.

C. 1-amalgam adhesive system, 2-composite, 3-amalgam.

D. 1-adhesive system, 2-fissure sealant, 3-composite.

E. 1- adhesive system, 2-composite, 3- fissure sealant.

Question nr 189

The root canal is defined as underfilled if the filling material is:

A. more than 0.5 mm short of the radiographic apex.

B. more than 1 mm short of the radiographic apex.

C. more than 1.5 mm short of the radiographic apex.

D. more than 2 mm short of the radiographic apex.

E. more than 3 mm short of the radiographic apex.

Question nr 190

Which of the following can influence the effectiveness of light-cured resin composite polymerization?

1) restorative material thickness;

2) photoinitiator concentration;

3) restorative material shade;

4) filler amount and its size.

The correct answer is:

A. only 1.

B. 1 and 2.

C. only 2.

D. 1, 2 and 3.

E. all the above.

Question nr 191

In which situations the determination of the working length by means of contemporary electronic apex locators may give false readings?

1) contact of the file to the metallic reconstructions;

2) presence of irrigating solution in the root canal;

3) presence of blood in the root canal;

4) tooth with an immature root.

The correct answer is:

- A.** 1,2.
- B.** 1,3.
- C.** 2,3.
- D.** 1,4.
- E.** 2,4.

Question nr 192

Antidepressants, antihypertensives and diuretics:

- A.** stimulate salivary flow and make dental caries more likely.
- B.** depress salivary flow and are cariostatic.
- C.** do not influence salivary secretion but react against dental caries.
- D.** depress salivary flow and make dental caries more likely.
- E.** do not influence salivary secretion and do not react against dental caries.

Question nr 193

The term „hidden caries” is used to define carious lesions:

- A.** located deeply subgingivally that are visible only after flap elevation.
- B.** diagnosed clinically only after prolonged air drying.
- C.** undetectable clinically, but visible on radiographs.
- D.** found only by applying caries detector dyes.
- E.** located under a poorly mineralized layer of the enamel.

Question nr 194

In an 18-year-old patient there was a slight caries lesion on the occlusal surface of tooth 47. The cavity was prepared and filled with a composite material. Healthy fissures on the occlusal surface and a pit on the buccal surface were sealed. What is the name of the performed procedure?

- A. invasive sealing.
- B. extension for prevention.
- C. preventive resin restoration.
- D. atraumatic restorative treatment.
- E. slot preparation.

Question nr **195**

Indicate the true statement concerning the hybrid layer:

- A. it is formed during bonding between composite material and enamel.
- B. it is formed by resin tags extending into the microporosities of enamel formed after etching.
- C. it is formed by resin that penetrates between collagen fibers of the demineralized layer of intertubular dentin.
- D. it is formed by resin tags extending into dentinal tubules.
- E. it is formed by resin binding with the smear layer and smear plugs.

Question nr **196**

Which of the following recommendations are dedicated to adults with high caries risk?

- A. individualized oral hygiene instructions and use of specialized cleaning aid, brushing with fluoride dentifrice (e.g., 1450 ppm fluoride), use of sugar substitutes (e.g., xylitol, sorbitol), control examination every 12-24 months.
- B. individualized oral hygiene instructions and use of specialized cleaning aid, brushing with fluoride dentifrice (e.g. 1/1%/5000 ppm NaF), use of sugar substitutes (e.g., xylitol, sorbitol), control examination every 12 months.
- C. individualized oral hygiene instructions and use of specialized cleaning aid, brushing with fluoride dentifrice (e.g. 1/1%/5000 ppm NaF), use of sugar substitutes (e.g., xylitol, sorbitol), control examination every 3 months.
- D. individualized oral hygiene instructions and use of specialized cleaning aid, brushing with fluoride dentifrice (e.g., 1450 ppm fluoride), use of sugar substitutes (e.g., xylitol, sorbitol), control examination every 9-12 months.

E. individualized oral hygiene instructions and use of specialized cleaning aid, brushing with fluoride dentifrice (e.g., 1450 ppm fluoride), control examination every 3 months.

Question nr **197**

Indicate the sets of irrigation fluids including only the fluids and their concentrations used in endodontic treatment:

- 1) 0.2% chlorhexidine (CHX), 5.25% ethylenediaminetetraacetic acid (EDTA);
- 2) 2.5% sodium hypochlorite, 15% citric acid;
- 3) 17% EDTA, 5.25% NaOCl;
- 4) 0.9% NaCl, 15% EDTA;
- 5) 50% citric acid, 2% CHX;
- 6) 3% H₂O₂, 5.25% NaCl.

The correct answer is:

- A.** 1,2,6.
- B.** 1,4,6.
- C.** 2,3,5.
- D.** 3,4,5.
- E.** 4,5,6.

Question nr **198**

Indicate the disadvantages of intrapulpal anaesthesia:

- 1) acutely painful injection;
- 2) short time of anaesthesia;
- 3) special instruments are required;
- 4) necessity of pulp chamber trepanation.

The correct answer is:

- A.** 1,2.
- B.** 1,3.
- C.** 1,2,3.
- D.** 1,2,4.
- E.** all the above.

Question nr **199**

Which of the following concerning xylitol **is false**?

- A. it is a polyhydroxy alcohol - a sugar substitute, nutritive sweetener.
- B. it reduces the level of cariogenic microorganisms in the oral cavity.
- C. it can be fermented by oral microorganisms.
- D. it has anticaries effect.
- E. it may have a laxative effect.

Question nr **200**

How long does it take for dental plaque to return to the initial pH level after carbohydrates consumption, a level which **does not** initiate demineralization of dental hard tissues?

- A. 5-10 minutes.
- B. 10-15 minutes.
- C. 15-20 minutes.
- D. 20-30 minutes.
- E. 30-60 minutes.

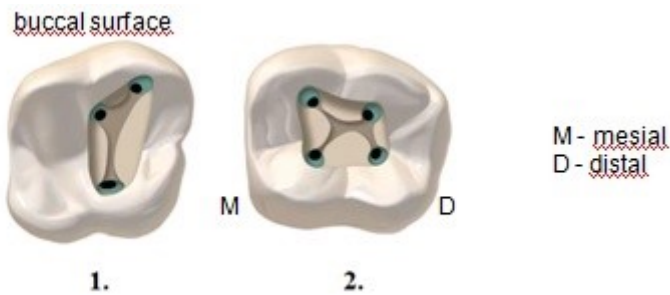
Question nr **201**

When preparing a class III cavity for an adhesive restoration, the enamel should be beveled at an angle of approximately:

- A. 10 degrees.
- B. 15 degrees.
- C. 25 degrees.
- D. 35 degrees.
- E. 45 degrees.

Question nr **202**

Indicate the correct answer concerning teeth in which it is possible to find root canal orifices in the same configuration as in the pictures below:



- A. (1) and (2) in the upper first molar.
- B. (1) in the upper first molar (2) in the upper second molar.
- C. (1) in the lower first molar (2) in the lower second molar.
- D. (1) in upper molars and (2) in lower molars.
- E. (1) and (2) in lower molars.

Question nr **203**

Which chemical reaction is responsible for the bleaching process of hard tooth tissues?

- A. polymerization.
- B. acid-base reaction.
- C. precipitation.
- D. oxidizing reaction.
- E. enzymatic reaction.

Question nr **204**

Choose the true statements concerning the smear layer:

- 1) this is a loosely adherent layer formed during the cutting of dentin and relates to the cavities prepared in the tooth crown;
- 2) this is loosely adherent layer formed during the cutting of dentin and relates to the cavities prepared in the tooth crown and root canal walls;
- 3) this is a tightly adherent layer formed during the cutting of dentin and relates to the cavities prepared in the tooth crown;
- 4) formation of smear plugs is beneficial because of the blocking of dentinal tubules and the elimination of dentin hypersensitivity;
- 5) smear layer promotes adhesion of filling materials to the tooth.

The correct answer is:

A. 1,4.

B. 1,5.

C. 2,4.

D. 2,5.

E. 3,5.

Question nr **205**

Indicate the proper definition of dental erosion:

A. loss of dental hard tissues as a result of chemical processes.

B. gradual loss of hard tissues caused by natural chewing.

C. pathological tooth wear caused by aging.

D. tooth wear caused by physical external factors.

E. loss of dental hard tissues as a result of chemical processes not involving bacteria.

Question nr **206**

Which of the following materials is particularly indicated for restoring teeth in patients with high caries risk to control caries?

A. hybrid composite resin.

B. nanofilled composite resin.

C. polyacid-modified composite resin.

D. ormocer.

E. glass-ionomer cement.

Question nr **207**

Indicate the true statement concerning incipient caries:

A. it is an irreversible process.

B. it is the effect of microleakage.

C. it can undergo remineralization.

D. it is characterized by a broken enamel surface but it does not penetrate into the dentine.

E. it is the effect of polymerization shrinkage of dental fillings.

Question nr **208**

Indicate **false** information concerning root canal retreatment:

A. root canal retreatment is indicated in the case of teeth with inadequately filled root canals and periapical lesions seen on the X-ray.

B. in the absence of proper preparation and filling of the root canal, surgical-endodontic or surgical treatment is possible.

C. final obturation of the root canals of the tooth re-treated endodontically is indicated immediately after root canal preparation.

D. final obturation of the root canals of the tooth re-treated endodontically should be postponed until the next visit.

E. temporary filling of the root canals of the tooth re-treated endodontically with Ca(OH)_2 dressing should be carried out immediately after the root canal preparation.

Question nr **209**

Indicate the true statements concerning the procedure of direct pulp capping:

A. it's indicated in the case of irreversible pulpopathy.

B. exposed pulp is coated with calcium hydroxide or zinc oxide with eugenol.

C. it consists in covering exposed or injured pulp with a biological dressing that contains calcium hydroxide or MTA.

D. direct pulp capping should result in the formation of sclerotic dentine.

E. it's indicated in the case of carious pulp exposure.

Question nr **210**

Laser Doppler flowmetry is used in endodontics for:

1) determination of the blood circulation in the dental pulp;

- 2) determination of the vitality of the pulp;
- 3) biostimulation of periapical lesion healing;
- 4) tooth crown transillumination test;
- 5) disinfection of the root canal system.

The correct answer is:

- A. 1,2.
- B. 1,3.
- C. 2,3.
- D. 3,4.
- E. 3,5.

Question nr 211

Standardized root canal preparation method can be used for preparing roots whose shape is:

- A. oval.
- B. straight.
- C. C-shaped.
- D. S-shaped.
- E. any of the above.

Question nr 212

Which of the following statements concerning carbamide peroxide is **false**?

- A. it breaks down to approximately 3.5-3.6% hydrogen peroxide.
- B. it is used for vital nightguard bleaching.
- C. it irritates skin and mucosa.
- D. it is also known as sodium perborate.
- E. it is available commercially and relatively frequently used in the concentration of 10-15%.

Question nr 213

Tooth wear caused by the regurgitation of hydrochloric acid, typical of anorexia and chronic alcoholism, is characterized by:

- A.** erosion lesions of the palatal surfaces of upper teeth and the buccal surfaces of lower teeth.
- B.** erosion lesions of the palatal and occlusal surfaces of upper anterior teeth as well as the buccal and occlusal surfaces of lower teeth.
- C.** abrasion lesions of the palatal and occlusal surfaces of upper teeth as well as the occlusal and buccal surfaces of lower teeth.
- D.** abrasion lesions of the buccal and occlusal surfaces of upper teeth as well as the lingual and occlusal surfaces of lower teeth.
- E.** erosion lesions of the buccal and occlusal surfaces of upper teeth as well as the lingual and occlusal surfaces of lower teeth.

Question nr 214

A 37-year-old patient was referred for endodontic treatment of the tooth 11 from another clinic. He complained of feeling sick, getting feverish and having severe pain aggravated by heated food and warm drinks. Cold alleviates the pain. The patient claims that he cannot even touch this tooth with the tongue because of the pain. What is the most probable diagnosis?

- A.** acute apical abscess.
- B.** periodontal abscess.
- C.** chronic apical periodontitis.
- D.** apical cyst.
- E.** irreversible pulpitis.

Question nr 215

Combine the forms of chlorhexidine given below with the appropriate chlorhexidine concentrations:

- a) 2%;
- b) 1%;
- c) 0.2%;
- 1) agent for root canals rinsing;
- 2) gel or paste;
- 3) mouthwash solution.

The correct answer is:

A. a-1, b-2, c-3.

B. a-1, b-3, c-2.

C. a-2, b-3, c-1.

D. a-2, b-1, c-3.

E. a-3, b-2, c-1.

Question nr **216**

Which of the following methods of stained teeth treatment is associated with the greatest risk of external cervical resorption?

A. enamel microabrasion.

B. thermocatalytic technique.

C. walking bleach technique.

D. "in-office" vital bleaching technique.

E. nightguard vital bleaching technique.

Question nr **217**

Enamel margin beveling in class IV before the application of the composite material **does not** result in:

A. increase in enamel etching efficiency.

B. removal of the prismatic enamel layer.

C. increase in fluoride content in the outer layer of the enamel.

D. improvement of aesthetics.

E. increase in adhesion surface size of the filling.

Question nr **218**

Which of the following concerning diagnostic procedure in the case of a fistula in the oral cavity is true?

A. fistula should be always pressed to evacuate the pus.

- B.** it is necessary to take the X-ray with a paper point to drain off the pus, which could blur the contrast of tissues.
- C.** if the diagnosis is uncertain the X-ray should be taken with a gutta-percha point inserted in the fistula canal.
- D.** in every case the X-ray should be taken with an endodontic file inserted in the root canal and the fistula.
- E.** to ensure the drainage the procedure of fenestration is performed to secure a permanent outflow of the pus.

Question nr **219**

Phosphoric acid is used for dentin etching and smear layer removal prior to the application of a bonding system of:

- A.** IV generation only.
- B.** IV or V generation.
- C.** IV or VI generation.
- D.** V or VI generation.
- E.** VI or VII generation.

Question nr **220**

Indicate the **incorrect** way of cavity opening and gaining access to the caries lesion located on the approximal surface of a posterior tooth:

- A.** in each case - through the occlusal surface with removing of the marginal ridge.
- B.** when the adjacent tooth is missing - through the direct access.
- C.** when the lesion is large - by removing the marginal ridge.
- D.** when the contact point is destroyed and the lesion extends towards the gingival margin - through the buccal or lingual surface, leaving the sound marginal ridge.
- E.** through the occlusal surface, leaving the marginal ridge intact when the lesion is small.

Question nr **221**

Which of the following **is not** a symptom of midroot perforations?

- A. fresh hemorrhage in the root canal.
- B. hemorrhage after a file insertion to the root canal.
- C. pain after a file insertion to the root canal.
- D. swelling.
- E. apex locator reading suggesting that the apex is reached although the file has gone into the root canal far less than its working length.

Question nr **222**

In which of the following scenarios it is necessary to retake the radiograph with the instrument for the purpose of working length determination?

- 1) tip of the instrument is 4 mm before the radiographic apex;
- 2) tip of the instrument goes beyond the apex and is located 3.5 mm further from the radiographic apex;
- 3) tip of the instrument is located 1.5 mm from the anatomical apex;
- 4) tip of the instrument is exactly at the radiographic apex.

The correct answer is:

- A. only 1.
- B. only 2.
- C. 1,2.
- D. 2,3.
- E. 3,4.

Question nr **223**

Indicate **the false** statement concerning the use of ultrasonic devices for root canal irrigation:

- A. acoustic microstreaming develops in the canal.
- B. it increases effectiveness of the solution.
- C. pulp remnants and debris are removed.
- D. irrigant temperature is decreased.

E. instruments that resemble K-file can be used.

Question nr **224**

Which cells found in the periodontal ligament proliferate in pathological conditions and give rise to cyst formation?

A. macrophages.

B. fibroblasts.

C. cementoblasts.

D. epithelial cells.

E. Hertwig cells.

Question nr **225**

During interview a patient reports that he suffered from heart failure three years ago. On X-ray type A internal resorption in tooth 22 is visible. The tooth is asymptomatic and responds correctly to mechanical and thermal stimuli. The patient maintains oral hygiene at a satisfactory level. Indicate the procedure recommended in this case:

A. immediate RCT and filling the resorption cavity with glass-ionomer.

B. immediate RCT and filling the root canal with calcium hydroxide.

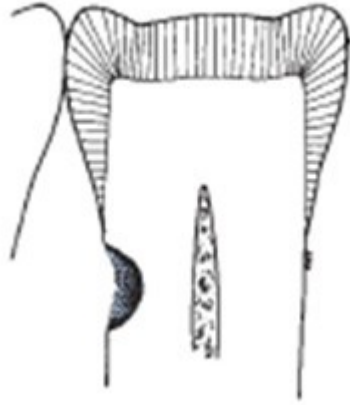
C. immediate RCT and filling the root canal with MTA for 6 months.

D. apical resection of the tooth after RCT and retrograde filling the resorption cavity with MTA.

E. extraction of the tooth.

Question nr **226**

Which restorative material is recommended for cavities localized as shown in the following picture?



- A. amalgam.
- B. composite resin.
- C. GIC.
- D. compomer.
- E. any of the above.

Question nr **227**

Which tooth sites are affected with caries in the cavities class I according to Black?

- 1) occlusal surfaces of the posterior teeth;
- 2) incisal edges of the front teeth;
- 3) cusp tip regions of the posterior teeth;
- 4) palatal surfaces of upper molars;
- 5) lingual surfaces of lower molars;
- 6) pits and fissures associated with additional cusps.

The correct answer is:

- A. 1,2,4.
- B. 1,4,5.
- C. 1,4,6.
- D. 2,3,4,5.
- E. 2,4,5,6.

Question nr **228**

Which of the following statements concerning dental injury diagnostics is true?

- 1) radiographs of the hard and soft tissues must be taken;
- 2) only radiographs of the hard tissues must be taken;
- 3) pulp vitality tests must be taken;
- 4) tooth mobility must be checked.

The correct answer is:

- A.** 2,3.
- B.** 1,3.
- C.** 2,3,4.
- D.** 1,3,4.
- E.** 3,4.

Question nr **229**

Indicate the **false** statement concerning endodontic irrigants:

- A.** chlorine freed from NaOCl dissolves necrotic tissue, forms chloroamine groups and facilitates the degradation of proteins.
- B.** recommended NaOCl concentrations range from 0.5% to 5.25%.
- C.** warming of a NaOCl solution increases its effectiveness.
- D.** NaOCl appears to be activated by EDTA.
- E.** 2% chlorhexidine exhibits strong antimicrobial properties.

Question nr **230**

On radiographs, images, such as short roots, pulpal obliteration and small bulbous crowns are characteristic of:

- A.** dentinogenesis imperfecta.
- B.** amelogenesis imperfecta.
- C.** hypodontia.
- D.** hypophosphatasia.
- E.** molar-incisor hypomineralization.

Question nr **231**

Dental plaque is an example of a biological membrane, called biofilm.
Indicate the true statement characterizing colonies of bacteria in the biofilm:

- A.** bacteria create a free formation connected to the tooth surface.
- B.** bacteria are not able to ferment.
- C.** streptococci are mainly present in dental plaque.
- D.** it is not an accidental colonization of micro-organisms but it is a community with mutual physiological interactions.
- E.** bacteria are not sensitive to antibacterial agents.

Question nr **232**

What kind of lesion can appear in the cavity under the filling with the carious tissues left at the bottom?

- A.** denaturation of dentin collagen.
- B.** hidden caries.
- C.** demineralization of the surface layer of enamel.
- D.** residual caries.
- E.** internal resorption of dentin.

Question nr **233**

A 34-year-old female came to the dental office with a deep carious lesion in tooth 46. The tooth did not respond to thermal stimuli and there was a small draining sinus tract adjacent to it. Periodontal tissues around the tooth were normal. What treatment should be performed in this case?

- A.** irrigation of the sinus tract outlet on the mucosa with 0.9% NaCl.
- B.** oral antibiotic therapy.
- C.** partial caries preparation and ZOE placement.
- D.** pulpotomy and calcium hydroxide dressing placement.
- E.** antiseptic root canal treatment.

Question nr **234**

Which of the following **is not** a possible consequence of the extrusion of irrigating solutions or root canal obturation materials beyond the apical foramen:

- A.** irritation of the periapical tissues.
- B.** necessity of root-end resection.
- C.** pain.
- D.** paresthesia.
- E.** root canal wall perforation.

Question nr **235**

Indicate the true information concerning amalgam restorations:

- 1) increased copper content results in an increased resistance to corrosion;
- 2) decreased copper content results in an increased resistance to corrosion;
- 3) mercury-tin phase is the most corrosive phase in amalgam;
- 4) silver-mercury phase is the most corrosive phase in amalgam;
- 5) copper-tin phase is the most corrosive phase in amalgam.

The correct answer is:

- A.** 1,3.
- B.** 1,4.
- C.** 1,5.
- D.** 2,3.
- E.** 2,5.

Question nr **236**

An endodontic instrument has a white handle, with number 15 and a circle symbol on it. What kind of instrument is it, and what is the diameter of its tip?

- A.** H file, diameter 0.015 mm.
- B.** H file, diameter 0.15 mm.
- C.** S file, diameter 0.015 mm.
- D.** S file, diameter 0.15 mm.

E. C file, diameter 0.015 mm.

Question nr **237**

Which of the following **is not** an advantage of chlorhexidine, a disinfectant and antiseptic used as a canal irrigant?

- A. antimicrobial activity.
- B. sustained antibacterial action.
- C. effectiveness against *Enterococcus faecalis*.
- D. little toxicity.
- E. ability to dissolve organic tissue.

Question nr **238**

Which of the following statements concerning pulp stones is **false**?

- A. they develop in the coronal pulp only.
- B. pulp stones can be attached to the pulp chamber wall or lie freely in the chamber.
- C. pulp stones can pose problems during performing endodontic treatment.
- D. due to their structure they are not always visible in radiographs.
- E. presence of a pulp stone is not a definite indication for endodontic treatment.

Question nr **239**

Pain provoked by biting but not related to cold/heat tests may suggest:

- A. cervical caries.
- B. irreversible pulpitis.
- C. incipient caries.
- D. pulp necrosis.
- E. reversible pulpitis.

Question nr **240**

Which of the following substances are used for treating dentin hypersensitivity?

- 1) potassium oxalate;
- 2) calcium phosphate;
- 3) adhesive resin;
- 4) aldehydes.

The correct answer is:

- A.** 1,2,3.
- B.** 1,2,4.
- C.** 1,3,4.
- D.** 2,3,4.
- E.** all the above.

Question nr **241**

In which of the following clinical cases it is possible to perform direct pulp capping?

- 1) tooth crown fracture with small pulp exposure (< 1 mm) in the first hours after trauma;
- 2) tooth with a carious cavity with a pulp polyp;
- 3) accidental pulp exposure in a noncarious cavity;
- 4) pulp exposure in a carious cavity.

The correct answer is:

- A.** 1,2.
- B.** 1,3.
- C.** 1,4.
- D.** 2,3.
- E.** 3,4.

Question nr **242**

What is the expected reaction of the healthy and not infected pulp after direct pulp capping with calcium hydroxide?

- A.** localized necrosis with a demarcation zone which appears after approximately 7 days and is rich in collagen.

- B.** coronal pulp in the state of reversible pulpitis.
- C.** resorption in the coronal pulp.
- D.** localized necrosis with a dentin bridge that appears after approximately 7 days.
- E.** aseptic necrosis of the pulp.

Question nr **243**

The indication for bicuspidization procedure is:

- A.** periapical lesion.
- B.** furcation pathosis from periodontal disease.
- C.** root canal wall perforation.
- D.** internal root resorption.
- E.** deep furcation.

Question nr **244**

What kind of canals should be expected when in the first upper premolar an additional third canal occurs?

- A.** pallatal, buccal-mesial, buccal-distal.
- B.** pallatal-mesial, pallatal-distal, buccal.
- C.** mesial, distal-buccal, distal-pallatal.
- D.** mesial-buccal, mesial-palatal, distal.
- E.** mesial, intermediate, distal.

Question nr **245**

Which of the following information about the pre-wedging procedure in conservative dentistry is true?

- 1) it involves wedge placement between adjacent teeth;
- 2) it involves sealing the matrix band with a wedge;
- 3) it allows a slight separation of teeth;
- 4) it protects gums and the rubber dam;

5) it is used for the gingiva retraction in class V cavities according to Black.

The correct answer is:

A. 1,2,3.

B. 1,3,4.

C. 1,3,5.

D. 2,3,4.

E. 3,4,5.

Question nr **246**

Which of the procedures should initial treatment plan cover?

1) extraction of gangrene roots of tooth 24;

2) composite veneer on tooth 11;

3) instruction of oral hygiene;

4) root coverage of dental recession in tooth 32;

5) vital pulp extirpation after the diagnosis of irreversible pulpitis in tooth 12;

6) broken instrument removal from the mesial canal of tooth 27, before planning prosthetic restoration.

The correct answer is:

A. 1,3,5.

B. 3,4,6.

C. 1,4,5.

D. 2,5,6.

E. 2,3,4.

Question nr **247**

Which of the following concerning bevelling of the enamel margin before placing composite resin restoration is true?

1) bevelling is recommended in the preparation of anterior teeth;

2) in posterior teeth bevelling should be placed on the occlusal surfaces or on other areas loaded with occlusal forces;

3) the bevel is prepared at 45-degree angle to the external tooth surface with a flame-shaped or round diamond instrument;

4) if the preparation extends gingivally onto the root structure, the bevel should be placed in the cementum;

5) bevelling results in the increase in enamel surface area for bonding and

improves the esthetic result of tooth-restoration interface.

The correct answer is:

- A.** 1,2,5.
- B.** 1,3,5.
- C.** 1,4,5.
- D.** 2,3,4.
- E.** 2,4,5.

Question nr **248**

In a patient endodontic treatment of tooth 46 was performed. Because of the inflammation in the furcation region, the tooth was separated by means of a vestibulo-lingual section in the bottom of the pulp chamber. Both parts of the tooth were left and then - prosthetically restored. What is the name of the carried out procedure?

- A.** bicuspidization.
- B.** hemisection.
- C.** radisection.
- D.** radectomy.
- E.** resection of the crown.

Question nr **249**

Trigeminal neuralgia:

- 1) typically presents in young individuals;
- 2) typically presents in individuals more than 50 years of age;
- 3) elicits sharp shooting pain on stimulation, such as light touch;
- 4) is characterized by strong spontaneous pain;
- 5) makes the teeth in this area vulnerable to falsenegative readings from vitality pulp tests.

The correct answer is:

- A.** 2,3.
- B.** 2,3,5.
- C.** 2,4.

D. 1,4,5.

E. 1,3.

Question nr **250**

Indicate the group of medications that **do not cause** hyposalivation:

A. anti-hypertensives, antidepressants, diuretics.

B. beta blockers, proton pump inhibitors, bronchodilators.

C. antihistamines, antibiotics, diuretics.

D. pilocarpine, nonsteroidal anti-inflammatory drugs, thyroid hormones.

E. thyroid hormones, antidepressants, beta blockers.

Question nr **251**

Indicate the **false** statement regarding a vertical tooth root fracture:

A. radiological examination is the basis for determining the line of a vertical root fracture.

B. too extensive root canal preparation can lead to a vertical root fracture.

C. cone-shaped root canal preparation reduces the risk of a root fracture.

D. presence of a deep narrow periodontal pocket, reaching the apical area suggests a vertical root fracture.

E. in vertical root fractures, the fracture line usually runs through the crown and root of the tooth.

Question nr **252**

Transillumination is used in endodontics to:

A. localize root canals.

B. confirm blood circulation in the pulp.

C. identify longitudinal crown fractures.

D. diagnose the pulp status of teeth with large restorations.

E. diagnose patients with pacemakers.

Question nr **253**

A 40-year-old patient reports to the dental office with severe pain of tooth 34 lasting for a week. During intraoral examination an extensive caries cavity of tooth 34 with demineralized dentin at the bottom is noticed. The tooth has an increased sensitivity to cold and shows no reaction on percussion.

Radiological examination did not reveal any periapical lesion. The optimal management in this case consists in:

- A.** observation.
- B.** general antibiotic therapy.
- C.** cavity preparation, indirect pulp capping.
- D.** cavity preparation, direct pulp capping.
- E.** pulp extirpation in anesthesia, root canal treatment.

Question nr **254**

In order to reduce polymerization shrinkage one can use:

- 1) „soft start” polymerization technique;
- 2) high-intensity light-curing technique;
- 3) bonding system dedicated to the composite;
- 4) thin layer of a flowable composite as a liner;
- 5) no thicker than 2 mm layers of conventional composite;
- 6) 2-5 mm thick layers of conventional composite;
- 7) no thicker than 6 mm layers of conventional composite.

The correct answer is:

- A.** 2,3,4,5.
- B.** 1,3,4,5.
- C.** 2,4,7.
- D.** 1,3,4,6.
- E.** 2,3,4,6.

Question nr **255**

A 23-year-old patient presents with a spontaneous pain of tooth 46 lasting for about 1 week. The pain has been much stronger since yesterday. The

clinical and radiological examination lead to the diagnosis of irreversible pulpitis. Because of no time to perform the indicated treatment on the same day the appointment is scheduled for 3 days later. What is the recommended treatment in this case?

- A.** prescribing antibiotic and analgesics and the next visit in 3 days.
- B.** trepanation of the pulp chamber in local anesthesia, an extirpation of the pulp from the chamber and the distal canal, application steroid-antibiotic preparation on the bleeding pulp and the next visit in 3 days.
- C.** trepanation of the pulp chamber in local anesthesia, application devitalizing preparation on the bleeding pulp and the next visit in 3 days.
- D.** trepanation of the pulp chamber in local anesthesia, a removal of the coronal pulp, applying the preparation of unsetting calcium hydroxide on root canal orifices and floor of the pulp chamber and the next visit in 3 days for creating a final restoration of the tooth.
- E.** trepanation of the pulp chamber in local anesthesia, performing a procedure of direct pulp capping using MTA on the bleeding pulp and the next visit in 3 days for creating a final restoration of the tooth.

Question nr **256**

During preparation of a cavity class II according to Black on the occlusal and mesial surface of tooth 36 in a 25-year-old patient, a carious spot is noted on the distal surface of tooth 35 with an intact enamel surface. On the X-ray a small demineralization of enamel and no demineralization in dentin is visible. No more active carious cavities are present in the patient and the oral hygiene is optimal. What kind of treatment of tooth 35 can you propose in this case?

- A.** tooth observation.
- B.** remineralization with clinical and radiological control.
- C.** preparation of the microcavity and filling with composite or GIC.
- D.** preparation of the cavity and filling using the sandwich technique.
- E.** tunnel preparation and filling the cavity with GIC.

Question nr **257**

Which of the following concerning irrigating solutions used in endodontic treatment is true?

- A.** chlorhexidine may be used alternatively with sodium hypochlorite.
- B.** EDTA has a broad spectrum of antimicrobial activity.
- C.** in the case of the extrusion of an irrigating solution beyond the apical foramen, sodium hypochlorite exhibits much greater toxicity to periapical tissues than chlorhexidine.
- D.** citric acid is especially recommended for irrigating root canals in teeth with persistent lesions in periapical tissues.
- E.** isopropyl alcohol may be used for smear layer removal.

Question nr **258**

Which of the following tissues are specialized connective tissues of mesodermal origin, formed from the dental papilla?

- A.** enamel and pulp.
- B.** cementum and pulp.
- C.** dentin and pulp.
- D.** only pulp.
- E.** enamel, dentin and pulp.

Question nr **259**

Changes in plaque pH following a rinse with a glucose solution were first observed by Stephan. How much time the acid plaque takes to return to its normal pH values in the region of 7?

- A.** 1 - 2 minutes.
- B.** 5 - 10 minutes.
- C.** 15 - 20 minutes.
- D.** 30 - 60 minutes.
- E.** 70 - 90 minutes.

Question nr **260**

What is the temperature above which guttapercha becomes liquid?

- A. 42 °C.
- B. 65 °C.
- C. 115 °C.
- D. 200 °C.
- E. 300 °C.

Question nr **261**

Which of the following factors are responsible for the abrasive formation of cavities?

- 1) endogenous acid activity;
- 2) exogenous acid activity;
- 3) overuse of toothpicks for cleaning interdental spaces;
- 4) holding a pipe between the teeth;
- 5) eccentric occlusal forces that cause tooth deflection.

The correct answer is:

- A. 1,2.
- B. 1,4.
- C. 2,5.
- D. 3,4.
- E. 3,5.

Question nr **262**

The fracture of the endodontic instrument in the canal can be avoided by:

- 1) not precurving the stainless steel instrument to the shape of the canal curvature before its insertion into the canal;
- 2) precurving the stainless steel instrument to the shape of the canal curvature before its insertion into the canal;
- 3) not using a damaged instrument;
- 4) not omitting successive sizes of applied instruments;
- 5) exerting marked force onto the instrument.

The correct answer is:

- A. 2,3,5.
- B. 2,4,5.

C. 2,3,4.

D. 1,3,5.

E. 1,3,4.

Question nr 263

Which of the following concerning ISO standards for root canal is true?

- 1) the number of root canal file refers to the diameter of its tip, which is measured in hundredths of a millimeter;
- 2) the number of root canal file refers to the diameter of its tip, which is measured in tenths of a millimeter;
- 3) traditional root canal files increase in the diameter of 0.04 mm per each subsequent millimeter of the length;
- 4) traditional root canal files increase in the diameter of 0.2 mm per each subsequent millimeter of the length;
- 5) the taper of traditional root canal files is 2%.

The correct answer is:

A. 1,3.

B. 1,4.

C. 1,5.

D. 2,4.

E. 2,5.

Question nr 264

Indicate the true statement concerning endodontic procedures:

A. pulpotomy is the surgical removal of the coronal and radicular pulp.

B. pulpectomy is a synonym of pulp amputation.

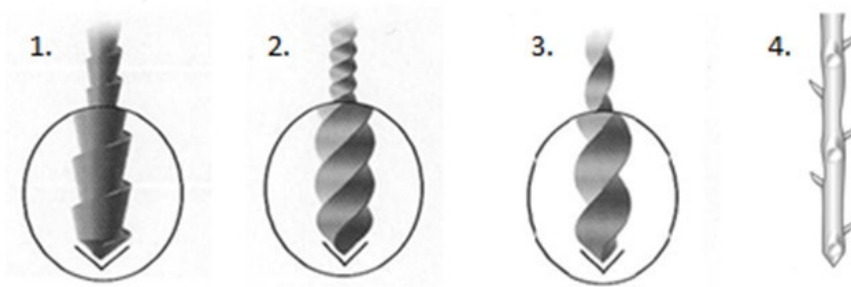
C. indirect pulp capping is performed by covering the pulpal wound first with non-setting calcium hydroxide and then with zinc dioxide with eugenol.

D. apexification means inducing a calcified barrier in a root with an open apex.

E. antiseptic root canal treatment is performed in teeth with irreversible pulpitis.

Question nr 266

Indicate correct names of the endodontic instruments shown in the following pictures:



- A. 1 - K -reamer, 2 - K-file, 3 - H-file, 4 - barbed broach.
- B. 1 - H-file, 2 - K-file, 3 - K-reamer, 4 - barbed broach.
- C. 1 - K-file, 2 - K-reamer, 3 - spreader, 4 - H-file.
- D. 1 - H-file, 2 - K-reamer, 3 - K-file, 4 - spreader.
- E. 1 - H-file, 2 - K-file, 3 - K-reamer, 4 - spreader.

Question nr 267

What is the taper of standard stainless steel endodontic hand files?

- A. .002.
- B. .02.
- C. .04.
- D. 4%.
- E. 6%.

Question nr 268

Which liquid is the most efficient and fastest in softening gutta-percha in the canal?

- A. sodium hypochlorite.
- B. EDTA.
- C. citric acid.

D. chloroform.

E. eugenol.

Question nr **269**

Choose the symptoms which usually accompany the perforation made within the root canal:

- 1) sudden pain;
- 2) sudden bleeding;
- 3) swelling of soft tissues;
- 4) increase a working length indicated by the electronic apex locator in comparison with the working length determined before;
- 5) change of the position of an endodontic file on the X-ray.

The correct answer is:

A. 1,2,4.

B. 1,3,4.

C. 2,3,4.

D. 2,3,5.

E. 1,2,5.

Question nr **270**

Indicate which part of a mandibular molar is left in the oral cavity after a bicuspidation (premolarization) procedure:

A. mesial.

B. distal.

C. lingual.

D. buccal.

E. mesial and distal.

Question nr **271**

The highest amounts of fluoride ions are released from glass-ionomer cements:

- A.** directly after the cement is placed in the cavity and the setting reaction concludes - it can be attributed to the release of fluoride ions from the glass particles in the material structure itself.
- B.** 30 days after the cement is placed in the cavity, which is due to the maturation of the cement structure.
- C.** 30 days after the cement is placed in the cavity, which is due to a gradual ion exchange within the cement matrix.
- D.** between the 3rd and 6th month after the cement is placed in the cavity; it can be attributed to high cement stability gained in this period.
- E.** the amounts of fluoride ions that are released from the cement do not change over time.

Question nr **272**

Which of the following is used for the removal of gutta-percha from the canal during root canal retreatment?

- 1) Hedström file;
- 2) nickel-titanium engine-driven files;
- 3) Lentulo spiral drill;
- 4) heated Hedström file;
- 5) 2% chlorhexidine.

The correct answer is:

- A.** 1,2,3.
- B.** 1,2,4.
- C.** 1,4,5.
- D.** 2,3,4.
- E.** 2,4,5.

Question nr **273**

Which of the following about adjusting the main standard gutta-percha cone to root canal walls is true?

- 1) size of the gutta-percha cone should be one size smaller than the last file used for root canal preparation along its working length;
- 2) while removing the fitted gutta-percha cone from the root canal one should overcome a slight resistance;
- 3) if gutta-percha cone placed in the root canal cannot reach the proper

length -one size larger cone should be selected;

4) if gutta-percha cone extends beyond the physiological foramen - one size larger cone should be selected;

5) after gutta-percha cone fitting taking of the X-ray is recommended.

The correct answer is:

A. 1,2,3.

B. 1,2,4.

C. 1,4,5.

D. 2,3,4.

E. 2,4,5.

Question nr 274

To improve the effectiveness of a sodium hypochlorite solution, it is recommended to:

1) heat the solution to body temperature;

2) cool the solution to 15°C;

3) mix the solution with CHX;

4) mix the solution with H₂O₂;

5) activate the solution by ultrasound;

6) increase the volume of the solution.

The correct answer is:

A. 1,3,4.

B. 2,3,5.

C. 1,5,6.

D. 2,4,5.

E. 1,4,6.

Question nr 275

A 22-year-old patient was referred to the endodontist for the root canal treatment of the tooth 16. During the treatment the dentist wanted to increase the efficiency of root canal irrigation with 2% sodium hypochlorite.

Which of the following methods can he use?

1) cooling of NaOCl solution below 20°C;

2) increasing the volume of NaOCl used during irrigation;

3) activation by mixing NaOCl with 2% chlorhexidine solution;

4) agitating of NaOCl solution by shaping the canal with files.

The correct answer is:

- A.** 1,2.
- B.** 1,3.
- C.** 2,3.
- D.** 2,4.
- E.** 3,4.

Question nr **276**

Circumferential filing used in endodontic treatment:

- 1) is a method of canal preparation;
- 2) is a method of canal obturation;
- 3) is used for large and not round canals;
- 4) is especially recommended for thin, curved and round canals.

The correct answer is:

- A.** only 1.
- B.** 2,3.
- C.** 2,4.
- D.** 1,3.
- E.** 1,4.

Question nr **277**

2% gutta-percha points have the highest percentage content of:

- A.** gutta-percha.
- B.** zinc oxide.
- C.** calcium hydroxide.
- D.** waxes.
- E.** opaquers.

Question nr **278**

Which endodontic-periodontal lesion is characterized by a narrow periodontal pocket?

- A. primary endodontic lesion.
- B. primary periodontal lesion.
- C. of mixed origin, endodontic-periodontal.
- D. all the above.
- E. none of the above.

Question nr **279**

A 25-year-old female came to the dental office complaining on a painless elevation of vestibular oral mucosa in the apical region of the tooth 14. On examination, when the lesion was pressed exudate appeared from the sinus tract that initially was purulent and then stained with blood. The most probable diagnosis is:

- A. apical cyst.
- B. acute apical abscess.
- C. chronic apical abscess.
- D. condensing osteitis.
- E. hyperplastic pulpitis.

Question nr **280**

Indicate the true statements concerning sclerotic dentin:

- 1) sclerotic dentin is a result of defense reaction of the pulp;
- 2) sclerotic dentin is a result of bacterial penetration into dentinal tubules;
- 3) sclerotic dentin is formed in the case of caries with rapid progression;
- 4) sclerotic dentin is formed in slowly advancing caries;
- 5) it is characterized by a decreased content of minerals;
- 6) it is formed within the primary dentin.

The correct answer is:

- A. 1,3,5.
- B. 1,3,6.
- C. 1,4,6.

D. 2,3,5.

E. 2,4,6.

Question nr **281**

What is the concentration of fluoride ions in a preparation that contains 2500 ppm F⁻?

A. 2.5%.

B. 0.25%.

C. 0.025%.

D. 0.0025%.

E. 0.00025%.

Question nr **282**

A 35-year-old patient reports with a single lesion of about 3 mm in diameter, located on the alveolar mucosa, which appeared about a week ago on the buccal side in the region of the root apex of tooth 23. The tooth 23 was painless, not tender on percussion. The X-ray picture revealed translucency by the apex of tooth 23. The above changes are most likely to be:

A. minor aphthous ulceration.

B. acute apical abscess.

C. sinus tract.

D. periodontal cyst.

E. apical granuloma.

Question nr **283**

Indicate the true statement on the use of rubber dams in endodontic treatment:

A. in endodontics the clamp is usually placed on a single tooth.

B. clamp has to be in contact with the tooth in two points.

C. during the endodontic treatment wingless clams are always used.

D. frame and clamp should be made of plastic to avoid corrosion when irrigants are used.

E. in endodontics thin rubbers are most useful.

Question nr **284**

Which of the following tissues belong to endodontium?

1) enamel;

2) dentin;

3) cement;

4) pulp.

The correct answer is:

A. 1,2.

B. 1,3.

C. 2,3.

D. 3,4.

E. 2,4.

Question nr **285**

What is the treatment plan in the case of a vertical root fracture of the maxillary incisor?

A. partial pulpotomy.

B. extirpation in anesthesia.

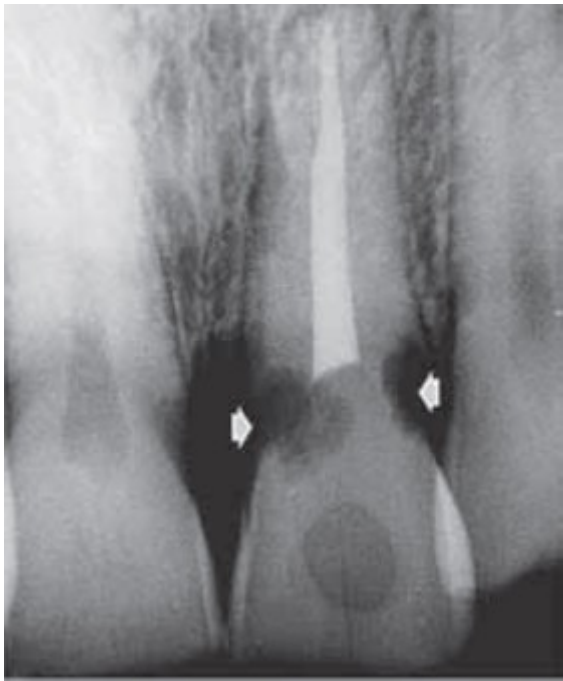
C. antiseptic root canal treatment.

D. apicoectomy.

E. extraction.

Question nr **286**

What could be the cause of the tooth resorption seen in the following radiograph?



- A. tooth fracture.
- B. internal tooth bleaching.
- C. tooth replantation.
- D. prosthetic treatment.
- E. endodontic treatment.

Question nr **287**

The yellowish discolouration of tooth crowns after trauma is caused by:

- A. pulpal haemorrhage.
- B. pulp necrosis.
- C. pulp calcification.
- D. development of microabscesses in the pulp tissue.
- E. haemoglobin degradation.

Question nr **288**

Indicate the true information concerning chlorhexidine used for irrigation during root canal treatment:

- 1) because of its properties it can be used instead of sodium hypochlorite;
- 2) it has strong antibacterial properties;
- 3) it doesn't dissolve organic tissues;

4) it removes the smear layer.

The correct answer is:

A. 1,2.

B. 1,4.

C. 2,3.

D. 2,4.

E. 3,4.

Question nr 289

Which of the following concerning direct pulp capping procedure **is false**?

1) indication for direct pulp capping is the presence of deep caries;

2) exposed pulp is covered with the preparation of calcium hydroxide or zinc oxide with eugenol;

3) it consists in putting a biological dressing of calcium hydroxide or MTA on the exposed or injured pulp;

4) direct pulp capping should result in reparative dentin formation;

5) contraindication to this procedure is carious pulp exposure.

The correct answer is:

A. 1,2.

B. 1,5.

C. 2,4.

D. 3,4.

E. 3,5.

Question nr 290

Indicate the true statements concerning the Gow-Gates block:

1) requires the use of the WAND system;

2) requires an injection into the mandibular foramen;

3) is performed in the patient's sitting position;

4) makes anesthesia of the lower molars possible;

5) requires only one injection;

6) limits the risk of trismus.

The correct answer is:

A. 1,2,3.

B. 2,4,5.

C. 1,3,4.

D. 4,5,6.

E. 1,2,6.

Question nr **291**

Which structure can be described as “the most recent layer of unmineralized dentin adjacent to the cell bodies of the odontoblasts”?

A. tertiary dentin.

B. secondary dentin.

C. predentin.

D. mantle dentin.

E. interglobular dentin.

Question nr **292**

Indicate the true information concerning benzodiazepines used for sedation in the cases of long dental procedures in hypersensitive patients:

1) induces amnesia;

2) provides a tranquillity effect;

3) provides an analgesic effect;

4) the most commonly used drug is articaine.

The correct answer is:

A. 1,2.

B. 1,3.

C. 2,3.

D. 2,4.

E. 3,4.

Question nr **293**

Indicate the true statements concerning the formation of dentin:

- 1) formation of dentin is completed just after tooth crown eruption;
- 2) dentin is being formed until the total formation of tooth roots;
- 3) dentin is being formed throughout the life of the pulp;
- 4) non-mineralized layer of newly formed dentin is called peritubular dentin;
- 5) non-mineralized layer of newly formed dentin is called predentin.

The correct answer is:

- A.** 1,4.
- B.** 1,5.
- C.** 2,5.
- D.** 3,4.
- E.** 3,5.

Question nr **294**

Indicate the true statement concerning anesthesia used in endodontic treatment:

- A.** during endodontic treatment of mandibular incisors it is necessary to administer anesthesia into the mandibular foramen.
- B.** intraosseous anesthesia needs special devices.
- C.** intrapulpal injection may be used only within the pulp chamber.
- D.** intrapulpal injection is rather painless and well tolerated by patients.
- E.** in periodontal ligament injection only one tooth is anesthetized, so this type of anesthesia is recommended as a reliable diagnostic test in irreversible pulpitis.

Question nr **295**

Which of the symptoms listed below is the most characteristic of VRF (vertical root fracture)?

- A.** spontaneous tooth pain after endodontic treatment.
- B.** pain on percussion in vertical direction.
- C.** pain on percussion in horizontal direction.
- D.** narrow, isolated periodontal pocket.

E. occurrence of radiological changes characteristic of endo-perio lesions present in the tooth after root canal treatment.

Question nr **296**

Indicate the best definition of erosion:

- A.** loss of dental hard tissues as a result of a chemical process.
- B.** loss of dental hard and soft tissues as a result of a chemical process.
- C.** loss of dental hard tissues as a result of a chemical process not involving bacteria.
- D.** loss of dental hard tissues as a result of a chemical process involving bacteria.
- E.** loss of dental hard and soft tissues as a result of a chemical process involving bacteria.

Question nr **297**

Indicate the true information concerning endodontium:

- A.** endodontium includes dentin and enamel maintaining structural and functional unity.
- B.** endodontium includes pulp and dentin maintaining structural and functional unity.
- C.** endodontium includes pulp and periodontium maintaining structural and functional unity.
- D.** endodontium includes only pulp.
- E.** endodontium is composed only of an inorganic substance.

Question nr **298**

Which of the following concerning the principles of endodontic treatment is true?

- 1) use of rotary Ni-Ti instruments while shaping the root canal does not eliminate completely the necessity to use hand instruments;
- 2) root canal with necrotic pulp should be prepared up to the radiographic apex;
- 3) coronal part of the root canal should be prepared to a greater extent than

the apical area of the canal;

4) recapitulation is performed in order to maintain root canal patency;

5) irrigation of the root canal should be started after finishing its mechanical shaping.

The correct answer is:

A. 1,2,4.

B. 1,3,4.

C. 1,2,5.

D. 2,3,4.

E. 2,3,5.

Question nr **299**

Indicate which restorative material should be used as the preferred choice in the case of root fillings in patients with high risk caries:

1) resin composite with microfiller;

2) glass-ionomer cement;

3) resin modified glass-ionomer;

4) ormocer;

5) recaldent.

The correct answer is:

A. 1,2.

B. 2,3.

C. 1,5.

D. 3,4.

E. 4,5.

Question nr **300**

Which of the following is a component of lubricants used in endodontics?

A. glycerol.

B. urea peroxide.

C. EDTA.

D. ethylenediaminetetraacetic acid.

E. all the above.

Question nr **301**

What is the clinical term for places which are not exposed to mechanical factors and where bacteria tend to settle down?

A. places of accumulation.

B. places of retention or stagnation.

C. places of demineralization.

D. places of bacterial integration.

E. selective places.

Question nr **302**

Which of the following devices is used in Schilder technique of warm gutta-percha vertical compaction?

A. Gutta Flow.

B. Touch'n Heat.

C. Obtura.

D. Thermafil.

E. Pessio reamers.

Question nr **303**

Symptoms associated with chronic periapical inflammation include:

- 1) bone sclerotization around the inflammation lesion;
- 2) thinning of the root cement;
- 3) cementoma formation;
- 4) adamantinoma formation;
- 5) presence of fistula.

The correct answer is:

A. 1,3,5.

B. 1,2,4.

C. 2,3,4.

D. 3,4,5.

E. 1,3,4.

Question nr **304**

Which of the following methods reduces the probability of resorption in the walking bleach technique?

A. sodium perborate is not used.

B. the bleaching agent should be removed after one day.

C. immediately after bleaching, a paste of calcium hydroxide is placed in the pulp chamber.

D. after the removal of the restoration from the pulp chamber and of 1-2 mm of the filling from the root canal, the gutta-percha of the root canal is sealed with amalgam.

E. immediately before bleaching, a paste of calcium hydroxide is placed in the pulp chamber.

Question nr **305**

Which of the following **is not** taken into consideration when assessing the fracture of a tooth crown with pulp exposure:

A. dimension of the fracture.

B. root development.

C. tooth position in the arch.

D. time after the trauma.

E. oral hygiene.

Question nr **306**

Which of the following are characteristic of non-cavitated enamel caries lesions termed "white spots"?

1) chalky white, opaque areas;

2) loss of translucency;

- 3) surface demineralization;
- 4) occurrence on the smooth enamel surface of the dental crown;
- 5) lack of mineral loss in the central zone.

The correct answer is:

- A.** 1,4,5.
- B.** 1,2,4.
- C.** 2,3,4.
- D.** 1,3,4.
- E.** 2,4,5.

Question nr **307**

Indicate the true statements regarding cone beam computed tomography (volumetric imaging):

- 1) does not generate ionizing radiation;
- 2) compared with X-ray, allows to define the anatomy of roots and canals more precisely;
- 3) it allows the detection of inflammatory changes in periapical tissues invisible on X-ray images;
- 4) it gives the possibility of an image analysis in two planes: axial and sagittal, but not in the frontal plane.

The correct answer is:

- A.** 1,2.
- B.** 2,4.
- C.** 1,4.
- D.** 2,3.
- E.** 1,3.

Question nr **308**

Indicate the correct information concerning apexification:

- 1) it concerns mature teeth;
- 2) the procedure of indirect pulp capping, partial or complete vital pulpotomy can be performed;
- 3) it concerns teeth with nonvital pulp;
- 4) it concerns teeth with vital pulp;
- 5) it means the medication-induced formation of a mineralised barrier in the

apex area of the root.
The correct answer is:

- A.** 1,2.
- B.** 1,3.
- C.** 2,4.
- D.** 3,5.
- E.** 4,5.

Question nr 309

In a 29-year-old patient the replantation of tooth 11, together with endodontic treatment was performed. After one year a periapical x-ray picture was taken. It revealed the absence of the periodontal ligament space and a blurred view of the root structures in relation to bone tissues. What is the correct diagnosis and indicated treatment?

- A.** ankylosis; immobilization for 7-10 days.
- B.** endo-perio lesion; secondary root canal treatment.
- C.** inflammatory root resorption; removal of the crown.
- D.** replacement resorption; no effective treatment, further follow-up.
- E.** replacement resorption; surgical procedure with the use of MTA.

Question nr 310

What is the microscopic shape of an early carious lesion on a smooth tooth surface?

- A.** it is usually seen to be cone-shaped, with the apex of the cone pointing towards the enamel-dentine junction.
- B.** it is usually seen to be cone-shaped, with the base of the cone pointing towards the enamel-dentine junction.
- C.** "scenic mountain landscape".
- D.** ring shaped.
- E.** diffusive canals.

Question nr **311**

What is the name of microanatomical elevations visible on the enamel surface, that usually lie parallel to the cemento-enamel junction and are separated with the grooves that are the endings of Tomes' processes?

- A. prisms.
- B. perikymata.
- C. Hunter-Schreger bands.
- D. Striae of Retzius.
- E. neonatal lines.

Question nr **312**

Which of the following **do not** decrease the salivary flow?

- A. antihypertensive drugs.
- B. diuretics.
- C. *Candida albicans* infections.
- D. antidepressants.
- E. head and neck radiotherapy.

Question nr **313**

Indicate the true statement concerning lysozyme contained in the saliva:

- A. increases the availability of oligosaccharides.
- B. binds free iron.
- C. lyses bacterial cells, releasing peptidoglycans.
- D. hydrolyses triglycerides to fatty acids and partial glycerides.
- E. agglutinates bacteria.

Question nr **314**

How deep should the spreader be inserted during root canal obturation with

the cold lateral compaction technique of GP?

- A.** at the beginning of the procedure to the Working Length (WL).
- B.** at the beginning of the procedure within 0.5 mm of the WL.
- C.** at the beginning of the procedure within 1 mm of the WL.
- D.** every time during the procedure within 1 mm of the WL.
- E.** every time during the procedure within 2 mm of the WL.

Question nr 315

What is the taper of hand endodontic instruments like K-files and reamers?

- A.** file diameters increase at a rate of 0.02 mm per running mm of their length.
- B.** they have variable .02 taper throughout one file.
- C.** they have constant .04 taper throughout one file.
- D.** diameter increases at a rate of 0.02, 0.04 or 0.06 mm per each mm of the file length depending on the size of the file.
- E.** it is a standard 2%, 4%, 6% taper depending on the size of the file.

Question nr 316

Indicate the true statement concerning tests assessing the state of dental pulp and periapical tissues:

- A.** positive result of percussion test indicates inflammation in the periodontal ligament.
- B.** increased tooth mobility is always connected with a loss of pulp vitality.
- C.** in order to assess the state of the pulp and periapical tissues it is sufficient to perform thermal test.
- D.** the most objective test allowing for finding the absence of blood circulation in the pulp is a cavity test.
- E.** sound pulp does not respond with pain to stimulation.

Question nr 317

In a 19-year-old patient clinical examination revealed generalized attrition of the teeth. Tooth crowns had a bulbous shape and were amber-brown. On X-ray shortened, thin roots and pulpal obliteration were visible. Which disease do the described signs indicate?

- A.** bruxism.
- B.** fluorosis.
- C.** amelogenesis imperfecta.
- D.** dentinogenesis imperfecta.
- E.** hypophosphatasia.

Question nr **318**

In tooth 11, B-type resorption (by Jeanneret's classification) - an internal root resorption without perforation was found. Which of the following methods of canal obturation can be used in this case?

- 1) filling the whole root canal with MTA;
- 2) CWT (Continuous Wave Technique) method;
- 3) filling the root canal only with a sealer.

The correct answer is:

- A.** all the above.
- B.** 1,2.
- C.** 2,3.
- D.** only 1.
- E.** only 2.

Question nr **319**

Where can you find root canals orifices shown in the pictures below?

Warm thermal pulp testing is usually applied with heated GP (gutta-percha). Indicate the correct preparation of the tooth surface to perform this test:

- A.** tooth surface should be covered with water from an air-water syringe.
- B.** tooth surface should be covered with a thin layer of lubricant (e.g. Vaseline).
- C.** tooth surface should be defatted.
- D.** tooth surface should be etched.
- E.** there is no special preparation of the tooth surface for applying warm thermal pulp testing.

Question nr **322**

Which of the following reasons for teeth staining is not classified as intrinsic discolorations?

- A.** discolorations due to fluorosis.
- B.** staining from tetracycline.
- C.** staining as a result of hereditary disorder.
- D.** tooth yellowing of the due to pulp chamber calcification after trauma.
- E.** staining resulting from rinsing with mouthwash containing chlorhexidine.

Question nr **323**

Indicate the true statements on the anatomy of the apical root:

- 1) apical foramen usually exists at the anatomic apex;
- 2) apical foramen does not usually exist at the anatomic apex;
- 3) in old teeth through cementum apposition the distance between AF and the anatomic apex diminishes;
- 4) in old teeth through cementum apposition the distance between AF and the anatomic apex increases;
- 5) distance between AF and the anatomic apex ranges from 0.5 mm to 3 mm;
- 6) distance between AF and the anatomic apex ranges from 0.8 mm to 5.5 mm.

The correct answer is:

- A.** 1,3,5.

B. 1,4,6.

C. 2,4,5.

D. 2,3,5.

E. 2,3,6.

Question nr **324**

Indicate the true statements concerning enamel adhesion:

- 1) it relies on the formation of microtags within the enamel structure;
- 2) etched enamel looks like a honeycomb under SEM magnification;
- 3) 37% phosphoric acid is the most commonly used etching agent;
- 4) acid-etching transforms the smooth enamel into an irregular surface ready for adhesion;
- 5) etching agent incorporates the smear layer into the interface tooth-composite;
- 6) enamel bonds chemically with the collagen from the bonding agent.

The correct answer is:

A. 1,3,4,5.

B. 1,2,3,4.

C. 2,3,5,6.

D. 3,4,5,6.

E. 3,4,5.

Question nr **325**

Indicate the **false** statement concerning sensory innervation of the periodontal ligament:

- A.** nerves are accompanied by arterioles.
- B.** it arises from the trigeminal nerve.
- C.** it records pressure changes in the ligament.
- D.** it arises from the facial nerve.
- E.** receptors are sensitive to tooth movement.

Question nr **326**

What is the most effective hand method of cleaning and shaping curved and calcified canals?

- A. step back technique.
- B. step down technique.
- C. crown down technique.
- D. balanced forces technique.
- E. standard preparation.

Question nr **327**

Which of the following concerning pre-wedging technique **is false**?

- A. the technique involves inserting a wedge between the teeth before starting preparation of a cavity on the proximal surface.
- B. it aims to obtain a slight separation of the teeth.
- C. it may protect gingiva during cavity preparation.
- D. it prevents rubber dam damage.
- E. it is especially recommended in the case of filling the cavity using PRR method.

Question nr **328**

Indicate the true statements regarding the preparation of root canals with the step-back technique:

- 1) after canal preparation with MAF, the subsequent larger files are placed at the length shorter than the working length determined earlier;
- 2) after canal preparation with MAF, the subsequent larger files are placed at the length equal to the working length determined earlier;
- 3) canal prepared with the step back technique has a cone shape;
- 4) the step-back technique is inferior to the standard preparation in terms of debridement and canal shape obtainment.

The correct answer is:

- A. 1,3.
- B. 2,4.

C. 3,4.

D. 1,4.

E. 2,3.

Question nr **329**

Match the following characteristics of the pulp stone with its type:

- 1) it is surrounded by pulp tissue;
- 2) it is partly fused with dentine;
- 3) it is surrounded entirely by dentine.

- a) free stone;
- b) adherent stone;
- c) embedded stone.

The correct answer is:

A. 1a, 2b, 3c.

B. 1b, 2a, 3c.

C. 1c, 2a, 3b.

D. 1b, 2c, 3a.

E. 1a, 2c, 3b.

Question nr **330**

Which of the following statements concerning nickel-titanium endodontic files is **false**?

A. it is possible to see the signs of material fatigue on the surface of the instrument and they can indicate a higher risk of breakage.

B. NiTi alloy is used for manufacturing both hand and engine-driven instruments.

C. they should be used only after the preparation of a straight-line access to the root canal.

D. they are less effective in preparing wide, oval root canals.

E. NiTi instruments enable a safer root canal preparation as they retain the original shape and curvature of the canal much better.

Question nr **331**

Which of the following pathologies may be asymptomatic?

- A. irreversible pulpitis.
- B. reversible pulpitis.
- C. pulp necrosis.
- D. chronic apical periodontitis.
- E. all the above.

Question nr **332**

The characteristic features of an endodontic periapical lesion on radiograph **do not** include:

- A. loss of the lamina dura apically.
- B. often a hanging-drop shape.
- C. lucency near the apex remaining in radiographs made at different cone angles.
- D. lesion development before it becomes visible on radiograph.
- E. horizontal and vertical bone loss.

Question nr **333**

Indicate the disadvantage of the front-surface dental mirror:

- A. placement of the reflection layer of rod on the glass surface.
- B. easy to damage.
- C. less ergonomic.
- D. smaller field of vision.
- E. inverted picture.

Question nr **334**

Indicate the **false** statement concerning odontoblasts:

- A. odontoblasts form a layer on the pulp periphery.

- B.** odontoblasts undergo cell divisions.
- C.** dental caries can damage odontoblasts, but if conditions are favorable, these cells can be replaced by new odontoblasts.
- D.** odontoblast cell bodies are interconnected through desmosomes.
- E.** morphology of the cells reflects the level of their activity.

Question nr **335**

The main cause of secondary root canal infection is:

- A.** *Treponema denticola*.
- B.** *Streptococcus species*.
- C.** *Enterococcus faecalis*.
- D.** *Candida albicans*.
- E.** C and D are correct.

Question nr **336**

Indicate the true statements regarding the effects of using chewing gum containing sugar substitutes as an additional hygienic procedure:

- 1) less than 30% reduction of caries;
- 2) reduction of the count of cariogenic microorganisms;
- 3) decrease in the concentration of bicarbonate ions in saliva;
- 4) increase in salivary lactoperoxidase;
- 5) increase in the Ca^{2+} concentration of ions in saliva.

The correct answer is:

- A.** 1,2,3.
- B.** 2,3,4.
- C.** 1,4,5.
- D.** 2,4,5.
- E.** 1,3,5.

Question nr **337**

The cariogenic effect of dietary carbohydrates is modified by other food components. Which ingredient of milk, to some extent, slows down the carious process?

- A. albumins.
- B. polyphenols.
- C. casein.
- D. lactose.
- E. lecithin.

Question nr **338**

Indicate the **false** statement concerning vertical root fracture (VRF):

- A. VRF is an indication for tooth extraction.
- B. VRF is mainly observed in the teeth after endodontic treatment.
- C. teeth in which the root canals were obturated using lateral condensation of gutta-percha are particularly susceptible to this complication.
- D. a wide periodontal pocket at the examined tooth may suggest VRF in that tooth.
- E. VRF may be asymptomatic.

Question nr **339**

A patient complaining of unaesthetic appearance of all their teeth comes to the dental office. On intraoral examination the presence of amber-brown, opalescent teeth with wear and normal but in many places broken enamel are noticed. On the X-ray bulbous crowns, shortened roots and an obliteration of pulp chambers and root canals are observed. Indicate the correct diagnosis of the described case:

- A. dentinogenesis imperfecta.
- B. amelogenesis imperfecta.
- C. molar-incisor hypomineralization.
- D. microdontia.

E. fluorosis.

Question nr **340**

Indicate the true statements concerning microfilled composites:

- 1) microfilled composites contain filler particles with a mean diameter of 0.04 μm ;
- 2) polymerization of the composites can be activated by an exposure to visible blue light of 470-480 nm wavelength;
- 3) microfilled composites contain filler particles with a mean diameter of 0.4 μm ;
- 4) resin-modified glass ionomer cements are used in the atraumatic restorative treatment technique;
- 5) hybrid composites are known as compomers.

The correct answer is:

- A. 1,5.
- B. 2,3.
- C. 1,2.
- D. 4,5.
- E. 2,4.

Question nr **341**

Which of the following **does not** play any role in the process of tooth tissue remineralisation?

- A. statherin.
- B. proline rich peptides.
- C. calcium.
- D. phosphate.
- E. lysozyme.

Question nr **342**

In the first upper molar the orifice of the accessory root canal is often located:

- A. directly in the central point on the floor of pulp chamber.

- B.** near the line between the buccal root canals' orifices.
- C.** near the line between the mesiobuccal and palatal root canal orifices.
- D.** near the line between the distobuccal and palatal root canal orifices.
- E.** 2-3 mm distally from the palatal root canal orifice.

Question nr **343**

What does the term bicuspidization mean?

- A.** carious or traumatic tooth tissue destruction of a furcation region, resulting in the separation of roots.
- B.** surgical division of roots of a maxillary or mandibular molar; both separated segments are retained in the oral cavity.
- C.** surgical division of roots of a mandibular molar; both separated segments are retained in the oral cavity.
- D.** surgical division of roots of a mandibular molar; one separated segment is removed from the oral cavity.
- E.** changes in upper premolar morphology making the tooth similar to the maxillary molar, e.g. the presence of 3 roots or 3 canals.

Question nr **344**

Which of the tooth surfaces are subject to wear in the course of attrition?

- 1) incisal edges;
- 2) proximal surfaces;
- 3) occlusal surfaces;
- 4) lingual surfaces of mandible teeth;
- 5) buccal surfaces of maxilla teeth.

The correct answer is:

- A.** 1,2,3.
- B.** 1,3,5.
- C.** 2,3,4.
- D.** 2,3,5.
- E.** 3,4,5.

Question nr **345**

What is the most common cause of variable resorption (ankylosis)?

- A. pulp amputation with the use of a Ca(OH)_2 preparation.
- B. teeth bleaching with a thermocatalytic method.
- C. periodontal treatment.
- D. orthodontic treatment.
- E. tooth luxation.

Question nr **346**

Which of the following statements concerning gutta-percha are **false**?

- 1) gutta-percha adheres to root canal walls;
- 2) gutta-percha shrinks as it cools down;
- 3) gutta-percha constitutes approximately 20% of a gutta-percha cone;
- 4) standardization of gutta-percha points is very precise - all points of a certain colour are the same in size;
- 5) gutta-percha dissolves after organic solvents (e.g. chloroform) are applied to it.

The correct answer is:

- A. 1,5.
- B. 2,5.
- C. 2,3.
- D. 1,4.
- E. 3,4.

Question nr **347**

During clinical examination of a 33-year-old female patient, on the lingual surfaces of upper teeth and on the occlusal surfaces of lower posterior teeth a lack of enamel and its thin borders was noted or a defective enamel surface was smooth and looked like polished. What etiological factors should be taken into account in this case?

- 1) pregnancy;
- 2) bulimia;
- 3) consumption of products containing vitamin C;

- 4) frequent drinking of fruit juices;
- 5) frequent swimming in the swimming pool;
- 6) alcohol abuse;
- 7) gastro-intestinal disorders.

The correct answer is:

- A.** 1,2,3,4.
- B.** 2,3,4,7.
- C.** 1,2,6,7.
- D.** 4,5,6,7.
- E.** 1,3,4,6.

Question nr **348**

Indicate the true statements concerning odontoblasts:

- 1) odontoblasts are pulp cells;
- 2) number of odontoblasts in the coronal pulp is higher than in the radicular pulp;
- 3) odontoblasts form a single cell layer on the pulp periphery;
- 4) odontoblasts may undergo numerous divisions because they are not differentiated adult cells;
- 5) odontoblasts are not sensitive to tooth disease and even caries does not affect these cells.

The correct answer is:

- A.** 1,2,3.
- B.** 3,4,5.
- C.** 1,3,4.
- D.** 2,3,4.
- E.** 1,4,5.

Question nr **349**

Indicate the true statements regarding dentin bridge formation after direct pulp capping:

- 1) occurs at the junction of the necrotic tissue and the vital, inflamed tissue after the application of calcium hydroxide of high pH;
- 2) consists of two layers: first developed tubular reparative dentin and atubular fibrous reparative dentin formed after stopping inflammation;

3) dentin bridge is thicker and more homogenous after the application of MTA compared with thinner dentinal bridge formed after the application of calcium hydroxide.

The correct answer is:

A. 1,2.

B. 1,3.

C. 2,3.

D. 1,2,3.

E. none of the above.

Question nr **350**

The diameter of yellow manual endodontic files may have at the DO point:

A. 0.08 mm, 0.2 mm, 1.2 mm.

B. 0.1 mm, 0.5 mm, 1.5 mm.

C. 0.2 mm, 0.5 mm, 1 mm.

D. 0.3 mm, 0.5 mm, 1.2 mm.

E. 0.1 mm, 0.3 mm, 0.9 mm.

Question nr **351**

Which of the following concerning recapitulation during root canal treatment with the Step-Back method:

1) recapitulation consists in removing the most coronally located parts of the canal pulp;

2) recapitulation is to ensure the patency of the canal to its physiological constriction;

3) recapitulation is performed with a sharp excavator;

4) recapitulation is performed with a file one size larger than the MAF;

5) recapitulation is performed with the MAF.

The correct answer is:

A. 1,3.

B. 1,5.

C. 2,3.

D. 2,4.

E. 2,5.

Question nr **352**

The term „hybrid layer” denotes:

- A.** layer that forms due to bacterial biofilm activity on a restoration surface.
- B.** inside layer of a carious lesion, i.e. the layer in which infected dentin contacts demineralized dentin.
- C.** layer that forms due to the penetration of adhesive resin into the matrix of collagen fibres.
- D.** layer that forms in bleaching, due to the oxygenation of the chemicals that are responsible for discoloration.
- E.** layer of cells at the apical constriction, i.e. where the cells of the periapical periodontium interdiffuse with the cells of dental pulp.

Question nr **353**

The most recently formed layer of dentin, unmineralized, closest to the pulp is called:

- A.** mantle dentin.
- B.** predentin.
- C.** interglobular dentin.
- D.** intertubular dentin.
- E.** tertiary dentin.

Question nr **354**

A pregnant woman in the fifteenth week of pregnancy presented to the dental office because of significant hypersensitivity of teeth occurring especially in response to thermal stimuli. On clinical examination a focal loss of enamel with thin borders was noted and the defective surface was very smooth and looked as if it was polished. The lesions were present on palatal surfaces of upper teeth and buccal and occlusal surfaces of lower teeth. What diagnosis should be considered in this case?

- A. erosion.
- B. caries.
- C. abrasion.
- D. abfraction.
- E. enamel hypoplasia.

Question nr **355**

Indicate the true statements concerning root cementum:

- 1) acellular cementum covers root dentin directly;
- 2) cementum thickness is the smallest at the root apex;
- 3) the extracellular matrix of cementum contains growth factors which are the source of periodontal regeneration;
- 4) cementum covering the root is the most vascularized in the cervical area.

The correct answer is:

- A. 1,2.
- B. 1,3.
- C. 2,3.
- D. 3,4.
- E. 1,4.

Question nr **356**

Indicate the true statements concerning C-type root canals:

- 1) their incidence depends on ethnicity;
- 2) most often occur in the first molars of the upper jaw;
- 3) the root canal orifice is located below the tooth's neck;
- 4) roots containing C-type canals are short and barrel-shaped;
- 5) category III in the Molton C-type canals classification concerns one wide canal extending from the bottom of the chamber to the root apex.

The correct answer is:

- A. 1,3.
- B. 2,4.
- C. 3,5.

D. 1,4.

E. 2,5.

Question nr **357**

Which of the following therapeutic results **cannot** be achieved with the use of calcium hydroxide?

- A.** reduction in bacterial load within the root canal.
- B.** stimulation of osseous tissue repair.
- C.** smear layer removal.
- D.** dissolution of tissues in teeth with resorption lesions.
- E.** apexification.

Question nr **358**

Indicate the true statement concerning abfraction:

- A.** is a result of tooth hard tissues wear caused by occlusal tooth-to-tooth contact.
- B.** it is destruction of tooth hard tissues by a chemical process not involving bacteria.
- C.** it has a shape of a wedge with smooth margins and is located in the enamel.
- D.** it is caused by strong excentric occlusal force action.
- E.** it is caused by bacteria.

Question nr **359**

Indicate the true statement concerning the body of the lesion - in the cross-section of an early caries lesion:

- A.** it is unaffected by the caries process and has the lowest pore volume.
- B.** is porous, the loss of minerals is in the range of 5 to 25%.
- C.** is an internal zone, where the loss of minerals is above 25%.

D. has the porosity of 2-4%.

E. is the deepest zone and its porosity is 1%.

Question nr **360**

The clockwise rotation (less than 180 degrees), then counterclockwise rotation (at least 120 degrees) with light apical pressure. Choose the technique of preparation which best corresponds to the description:

A. step-back technique.

B. step-down technique.

C. passive step-back technique.

D. balanced force technique.

E. recapitulation.

Question nr **361**

Which processes occur in dental pulp and dentine with aging?

A. decrease in the resistance to cariogenic factors.

B. dental pulp mass increase.

C. increase in the number of collagen fibers.

D. increase in the number of blood vessels.

E. excitability threshold decrease.

Question nr **362**

Which part of an early caries lesion in enamel shows the greatest loss of mineral substance?

A. translucent zone.

B. dark zone.

C. body of the lesion - on the periphery.

D. body of the lesion - in the center.

E. surface zone.

Question nr **363**

How many types of different root canal configurations are included in Vertucci's classification?

- A.** 4.
- B.** 5.
- C.** 6.
- D.** 7.
- E.** 8.

Question nr **364**

The anticurvature filing method consists in:

- A.** protection of curvature forming during root canal preparation.
- B.** use alternately step-back and step-down method in order to straighten the canal in its apical one third.
- C.** selective dentin removal from the bulky wall.
- D.** selective dentin removal from the inner/furcal wall.
- E.** straightening the root canal near the orifice.

Question nr **365**

Which of the following is considered to be the defense reaction of the dentine-pulp complex?

- 1) primary dentine;
- 2) secondary physiologic dentine;
- 3) sclerotic (translucent) dentine;
- 4) tertiary dentine (reactionary);
- 5) pulpal inflammation.

The correct answer is:

- A.** 2,3,4.
- B.** 3,4,5.
- C.** 1,3,4.

D. 2,3,5.

E. all the above.

Question nr **366**

Indicate the **false** statement concerning sclerotic dentin (translucent dentin):

A. is homogenous macroscopically and looks like glass.

B. its hypermineralized areas may be seen on radiographs as zones of increased radiolucency.

C. is formed only in the presence of a vital odontoblasts layer.

D. its permeability is greatly reduced compared with normal dentin.

E. has a bright image in histological sections.

Question nr **367**

What is the influence of sugar free chewing gum with xylitol on saliva secretion?

A. stimulated saliva contains more hydroxyl ions, which are an important alkalizing factor.

B. saliva secreted while chewing gum has a higher temperature and that increases its pH.

C. chewing gum stimulates an inorganic substance release from tooth tissues and that increases pH of the saliva.

D. stimulated saliva contains more carbohydrates ions, which are an important buffering factor increasing pH of the saliva.

E. chewing gum does not influence the salivary gland stimulation.

Question nr **368**

According to the Black's classification the lowest C-factor (defining amount of shrinkage of the material) is observed in the cavities of:

A. class I.

B. class II.

C. class III.

D. class IV.

E. class V.

Question nr **369**

Indicate the true statement concerning diagnostic tests used in dentistry:

A. selective anesthesia can be used for identification of a painful tooth when the patient cannot identify if the pain comes from the left or right side.

B. to perform selective anesthesia a mandibular nerve block should be done.

C. pain on palpation of the mucosa overlying the root apex may indicate reversible pulpitis.

D. percussion test should be performed with a big round condenser.

E. mobility test determines the status of odontoblast's processes.

Question nr **370**

Which of the following has a drying property in the case of a severe inflammatory exudation in the root canal?

A. setting calcium hydroxide.

B. non hardening $\text{Ca}(\text{OH})_2$.

C. chlorhexidine.

D. metronidazole.

E. antibiotic-steroid agent.

Question nr **371**

Indicate the true statements concerning dental plaque:

1) pellicle, bacteria free organic film, is the first stage of dental plaque formation;

2) *Streptococcus salivarius* is the first bacteria to inhabit the newborn's oral cavity;

3) at the early stage of plaque formation aerobic bacteria are present but more anaerobic species appear as the plaque matures;

4) "corn cobs" are mostly made of *Staphylococcus* and *Streptococcus*;

5) the growth of plaque is a random accumulation of bacteria and their products.

The correct answer is:

- A.** 1,2,3.
- B.** 2,4,5.
- C.** 1,4,5.
- D.** 2,3,5.
- E.** 1,3,4.

Question nr **372**

In which teeth dens invaginatus (dens in dente) occurs most frequently?

- A.** maxillary central incisors.
- B.** maxillary lateral incisors.
- C.** maxillary and mandibular incisors.
- D.** maxillary premolars.
- E.** mandibular premolars.

Question nr **373**

Indicate the true statements regarding the anatomy of the mandibular molars:

- 1) mandible molars usually have three roots;
- 2) outline of the access preparation is oval in shape;
- 3) lower first molar may have an additional, separate distal root;
- 4) there may be three root canals in the mesial root.

The correct answer is:

- A.** 1,3.
- B.** 1,2.
- C.** 3,4.
- D.** 2,3.
- E.** 2,4.

Question nr **374**

Which of the statements concerning Hedstroem files is true?

- 1) H-file is more prone to breaking than a K-file;
- 2) due to its structure, an H-file is very effective while rotating;
- 3) cross-sectional shape of an H-file is triangular;
- 4) H-file cuts dentin mainly the moment the file is inserted into the canal.

The correct answer is:

A. only 1.

B. only 2.

C. 1,2.

D. 2,3.

E. 3,4.

Question nr **375**

What is the shape of endodontic access in central upper incisor in young people:

A. rectangular.

B. trapezoidal.

C. rhomboid.

D. oval.

E. triangular.

Question nr **376**

The C-shaped root canal configuration is observed most commonly in:

A. mandibular second molars.

B. mandibular second premolars.

C. maxillary third molars.

D. maxillary first premolars.

E. maxillary second premolars.

Question nr **377**

This method uses the arc-lamp producing blue light, analyzer and monitor. Computer analysis provides quantitative assessment of the mineral loss in dental hard tissues. In examination a healthy tooth shows green fluorescence; demineralization is manifested as a dark stain. Which method of diagnosing caries is the description associated with?

- A. DI-FOTI.
- B. Diagnodent.
- C. QLF.
- D. ECM.
- E. EIS.

Question nr **378**

Indicate the true statements about EDTA and urea based lubricants used in endodontics:

- 1) have strong bactericidal potential;
- 2) have the ability to bind calcium ions from the root dentin surface;
- 3) do not require rinsing before root canal filling;
- 4) may be the cause of acute inflammatory symptoms from periapical tissues.

The correct answer is:

- A. 3,4.
- B. 1,4.
- C. 1,2.
- D. 2,3.
- E. 2,4.

Question nr **379**

A patient comes to the dental office with painful tooth 44, in which a resin composite restoration was placed a week ago. The initial diagnosis is: symptomatic apical periodontitis. Which of the following symptoms **is not** observed in this case?

- A.** pain on mastication.
- B.** mild spontaneous pain.
- C.** pain on percussion.
- D.** elevation of the tooth in the socket.
- E.** draining intraoral sinus.

Question nr **380**

Indicate the true statements on attrition:

- 1) concerns the pericervical area of the buccal surfaces of teeth;
- 2) concerns the proximal surfaces of teeth;
- 3) concerns the occlusal surfaces and incisal edges of teeth;
- 4) is the result of chewing and tooth-to-tooth contacts;
- 5) is the result of tooth-to-foreign body contacts.

The correct answer is:

- A.** 1,2,4.
- B.** 1,2,5.
- C.** 1,3,4.
- D.** 2,3,4.
- E.** 2,3,5.

Question nr **381**

Para-chloroaniline (PCA) may be formed during canal irrigation as a result of the interaction between:

- A.** sodium hypochlorite and chlorhexidine.
- B.** chlorhexidine and EDTA.
- C.** sodium hypochlorite and EDTA.
- D.** sodium hypochlorite and hydrogen peroxide.
- E.** sodium hypochlorite and citric acid.

Question nr **382**

Which of the following statements concerning the properties of chlorhexidine (CHX) are true?

- 1) it has strong bactericidal properties;
- 2) it has bleaching properties;
- 3) CHX removes the organic part of the smear layer;
- 4) CHX removes the inorganic part of the smear layer;
- 5) it has organic tissue dissolving properties.

The correct answer is:

A. 1,3.

B. 1,4.

C. 1,2.

D. 1,5.

E. only 1.

Question nr 383

A positive reaction on percussion of the tooth facial surface but not the occlusal one may indicate:

A. acute periapical inflammation.

B. irreversible pulpitis.

C. periodontal inflammation.

D. pulp necrosis.

E. transverse root fracture.

Question nr 384

The simultaneous irrigation of root canal space with sodium hypochlorite and chlorhexidine leads to:

A. smear layer removal.

B. better cleanness of canal walls and dentinal tubules.

C. betterment of chelating properties of NaOCl.

D. drying effect.

E. parachloroaniline precipitation.

Question nr **385**

Indicate the true information about entering the cavity (access to the caries lesion) on the proximal surface of anterior teeth:

- 1) usually lesions on the proximal surfaces of anterior teeth should be opened from the labial surface;
- 2) in the case of crowding teeth and so an easier access they can be opened from the labial surface;
- 3) labial access is allowed in the cases where an already existing filling located on the labial surface requires replacement;
- 4) lingual/palatal access is recommended in each case.

The correct answer is:

A. 1,2.

B. 1,3.

C. 2,3.

D. 2,4.

E. 3,4.

Question nr **386**

Select the true statements regarding the elements of saliva:

- 1) lysozyme absorbs free iron ions;
- 2) lactoferrin doesn't present antimicrobial activity;
- 3) secretory immunoglobulin A and mucins present agglutinative activity;
- 4) lysozyme and secretory immunoglobulin A are salivary enzymes;
- 5) mucins, lactoferrin and secretory immunoglobulin A support remineralisation.

The correct answer is:

A. 1,5.

B. 2,3.

C. 3,4.

D. only 3.

E. only 5.

Question nr **387**

Which of the following concerning conventional self setting glass-ionomer materials **is false**?

- A.** demonstrate chemical adhesion to enamel and dentin.
- B.** create chemical bond with calcium ions in tooth tissues.
- C.** create weaker connections with enamel than resin composite.
- D.** create hybrid layer after tooth tissue conditioning with polyacrylic acid.
- E.** absorb fluoride ions present in the oral cavity.

Question nr **388**

Which of the statements concerning direct pulp capping performed with the use of MTA is correct?

- A.** the whole cavity has to be restored with MTA; after 4 days some part of the restoration has to be removed and replaced with definitive restoration.
- B.** MTA is placed directly on exposed pulp, and resin-modified glass-ionomer cement has to be placed directly over the material.
- C.** MTA is placed directly on exposed pulp, and the remaining part of the cavity has to be restored using zinc-phosphate cement.
- D.** MTA is placed directly on exposed pulp, then a moist cotton pellet has to be placed on MTA, and finally, a temporary restoration should be inserted into the cavity.
- E.** MTA is not indicated for performing direct pulp capping procedures.

Question nr **389**

Indicate the correct statement concerning techniques of root canal preparation:

- A.** standardized technique is recommended in straight and curved canals.
- B.** anticurvature technique is used to avoid a strip perforation of the root canal furcal wall.
- C.** balanced force technique involves introducing a small size instrument to a previously established working length to remove accumulated debris from the root canal and to maintain canal patency.

D. when Ni-Ti rotary instruments are used the canals are usually prepared using the step-back technique.

E. in crown-down technique the apical part of the root canal is prepared first, and then the coronal part.

Question nr **390**

Which irrigant **does not** remove any part of the smear layer?

A. citric acid.

B. chlorhexidine.

C. NaOCl.

D. EDTA.

E. each of the above does remove organic or inorganic part of the layer.

Question nr **391**

Which of the following statements concerning internal root resorption is true?

A. it is an indication for endodontic treatment.

B. granulation tissue can be completely removed from the root canal by means of endodontic instruments only.

C. pulp tissue in teeth with active internal root resorption is always necrotic within the whole root canal.

D. lateral condensation of cold gutta-percha is the obturation method of choice for teeth with internal root resorption.

E. clinical picture of internal resorption lesions is completely different than the one of external cervical resorption.

Question nr **392**

Which of the following are removed with EDTA?

A. mineralized tissues.

B. organic substances.

C. pulp of the tooth.

D. dentin collagen fibres.

E. periodontium.

Question nr **393**

Which tooth sites are affected with caries in the cavities class VI according to Black?

- 1) occlusal surfaces of the posterior teeth;
- 2) incisal edges of the front teeth;
- 3) cusp tip regions of the posterior teeth;
- 4) pits and fissures associated with additional cusps.

The correct answer is:

A. 1,2.

B. 1,4.

C. 2,3.

D. 2,4.

E. 3,4.

Question nr **394**

Carbamide peroxide is used widely nowadays for dentist-prescribed at-home bleaching procedures. When it comes in contact with saliva and other oral fluids, it breaks into two compounds. Which product of this chemical reaction is the active ingredient, i.e. which product and at which concentration is directly responsible for the whitening of the tooth structure?

A. 3% hydrogen peroxide.

B. 7% hydrogen peroxide.

C. 3% urea.

D. 7% urea.

E. 3% urea carbamate.

Question nr **395**

Diagnodent device works on the basis of the phenomenon of:

- A. laser-induced fluorescence.
- B. AC (alternating current) impedance spectroscopy.
- C. electric resistance.
- D. transillumination.
- E. digital subtraction radiology.

Question nr **396**

Indicate the true statements concerning the cementum:

- 1) cementum is formed continuously throughout the life;
- 2) cementum may extend onto the inner wall of the root canal;
- 3) cellular cementum predominates in the coronal part of the root;
- 4) cementum is vascularized and innervated.

The correct answer is:

- A. 1,2.
- B. 3,4.
- C. 1,3.
- D. 2,4.
- E. all the above.

Question nr **397**

Which of the following describing tooth fluorosis is **false**?

- A. results from an enamel defect during tooth development.
- B. develops as a result of excessive fluoride ingestion during tooth development.
- C. can also develop in adults as a result of long term exposure to topical fluoride.
- D. it is intrinsic discoloration.
- E. symptoms are not limited to a single tooth.

Question nr **398**

Which of the following irrigators for root canals dissolve organic tissue:

- 1) sodium hypochlorite;
- 2) chlorhexidine;
- 3) citric acid;
- 4) EDTA;
- 5) hydrogen peroxide.

The correct answer is:

- A.** 1,2.
- B.** 1,4.
- C.** 1,5.
- D.** 2,5.
- E.** 3,4.

Question nr **399**

Which type of the root canal configuration according to Vertucci can be assigned to a tooth with three separate root canals starting in the pulp chamber and ending in the apical region?

- A.** type IV.
- B.** type V.
- C.** type VI.
- D.** type VII.
- E.** type VIII.

Question nr **400**

Which of the statements concerning secondary dentin is true?

- A.** the thickness of secondary dentin layers, a dentin which is apposed within the crown, is not even on all tooth surfaces.
- B.** in contrast to primary dentin, tubules in secondary dentin are completely straight and do not bend.
- C.** secondary dentin is mainly atubular.
- D.** apposition of secondary dentin forms until the root of the tooth becomes

mature.

E. secondary dentin is apposed mainly in response to pathological stimuli, such as caries or occlusal trauma.

Question nr **401**

Match the histologic pattern and proper diagnosis:

- 1) central cavity filled with eosinophilic fluid is lined by stratified squamous epithelium;
 - 2) an increase in density of trabecular bone and inflammation;
 - 3) localized destructive lesion of liquefaction necrosis containing disintegrating polymorphonuclear leukocytes, debris and cell remnants and an accumulation of purulent exudate;
 - 4) sinus tract lined partially or totally by epithelium surrounded by inflamed connective tissue;
 - 5) polymorphonuclear leukocytes and macrophages visible within a localized area at the apex;
- a) condensing osteitis;
 - b) apical cyst;
 - c) chronic apical abscess;
 - d) acute apical periodontitis;
 - e) acute apical abscess.

The correct answer is:

- A.** 1b, 2a, 3e, 4c, 5d.
- B.** 1a, 2b, 3c, 4d, 5e.
- C.** 1a, 2d, 3c, 4d, 5e.
- D.** 1b, 2a, 3c, 4e, 5d.
- E.** 1b, 2d, 3a, 4e, 5c.

Question nr **402**

Which of the following statements concerning enamel hypoplasia is true?

- A.** it is a qualitative disorder of enamel.
- B.** hypoplastic lesions develop due to the fact that enamel matrix is defective.
- C.** usually, the lesions are located unilaterally, just as other developmental disorders of enamel.

D. the thickness of enamel within hypoplastic lesions is usually normal.

E. hypoplastic enamel lesions are always white.

Question nr **403**

For better apical seal of the master gutta-percha point, its apical part can be solvent-softened before being put into the root canal. Which liquid is recommended as a solvent in this case?

A. chloroform.

B. isopropyl alcohol.

C. eugenol.

D. parachlorophenol.

E. glutaraldehyde.

Question nr **404**

Why shouldn't the demineralized carious tissue be left in the area of the dentine-enamel junction during the cavity preparation?

1) because none of the restorative materials forms a perfect cavity seal;

2) because the progress of caries will lead to the obliteration of dentinal tubules in the DEJ region;

3) because the carious disease will progress more rapidly;

4) because the tooth color can change.

The correct answer is:

A. 1,2.

B. 1,3.

C. 2,3.

D. 2,4.

E. 3,4.

Question nr **405**

Indicate the true statements concerning gutta-percha cones:

1) their adhesion to the dentin is very good;

2) they should not be sterilized;

3) they are available in standardized and conventional form;

4) standard gutta-percha cones can be found in the following sizes: XF, MF, F, FM, M, L;

5) gutta-percha cones can be disinfected in a sodium hypochlorite solution.

The correct answer is:

A. 1,2,3.

B. 1,4,5.

C. 1,3,4.

D. 2,3,4.

E. 2,3,5.

Question nr 406

The characteristic feature of an early enamel lesion, visible in its histological picture, is that it is covered by the layer of:

A. healthy enamel.

B. highly porous enamel.

C. relatively intact enamel.

D. demineralized enamel.

E. dark enamel.

Question nr 407

Chemomechanical preparation of the root canal with copious amounts of 5% sodium hypochlorite irrigation, calcium hydroxide as intracanal dressing, followed by obturation preferably with flowable gutta-percha is the treatment of choice in the case of:

A. irreversible pulpitis.

B. acute apical periodontitis.

C. pulpal necrosis.

D. internal root resorption.

E. external cervical root resorption.

Question nr **408**

Assign the proper functions to the saliva components:

- 1) lactoperoxidase;
 - 2) amylase;
 - 3) lysozyme;
 - 4) lipase;
 - 5) glycoproteins;
 - 6) lactoferrin.
- a) lyses bacteria cells;
 - b) hydrolyzes triglycerides to free fatty acids;
 - c) cleaves 1-4 glucoside bonds;
 - d) agglutinates bacteria in the oral cavity;
 - e) inhibits growth of some iron-dependent microbes;
 - f) oxidizes thiocyanates in the presence of hydrogen peroxide.

The correct answer is:

- A.** 1e, 2d, 3b, 4a, 5c, 6f.
- B.** 1c, 2a, 3b, 4d, 5f, 6e.
- C.** 1a, 2b, 3c, 4d, 5e, 6f.
- D.** 1f, 2b, 3c, 4a, 5d, 6e.
- E.** 1f, 2c, 3a, 4b, 5d, 6e.

Question nr **409**

Indicate the true statements regarding calcium hydroxide:

- 1) it is the most common material used for vital pulp therapy;
- 2) it has high pH;
- 3) it needs at least 6 hours to set properly;
- 4) it causes necrosis to the superficial layers of pulp;
- 5) treatment of the exposed pulp with the use of this material requires a two-step procedure.

The correct answer is:

- A.** 1,2.
- B.** 1,2,4.
- C.** 1,3,5.
- D.** 3,5.

E. only 2.

Question nr 410

Indicate **the false** statement concerning inactive caries:

- A. it is a lesion that does not progress.
- B. it is the area in which enamel remineralization took place.
- C. it is the area less resistant to acid action than normal enamel.
- D. it is the area in which secondary enamel maturation occurred.
- E. it is the enamel area in which the dental plaque retention is not observed.

Question nr 411

The balanced force technique can be used for mechanical root canal preparation. Which of the following statements concerning this technique are true?

- 1) order of movements made with the instrument is as follows: clockwise direction (CW) - counterclockwise direction (CCW) - clockwise direction (CW);
- 2) order of movement is: CCW - CW - CCW;
- 3) range of movement is the same in both directions (e.g. 90 degrees CW and 90 degrees CCW);
- 4) when the instrument is moved CCW, the clinician should press apically;
- 5) balanced force technique is used mainly for preparing large and straight canals.

The correct answer is:

- A. 1,3.
- B. 2,3.
- C. 1,4.
- D. 3,5.
- E. 2,5.

Question nr 412

Indicate the mechanism of the adhesion of composite materials to enamel:

- A. creation of a chemical connection due to the interaction of calcium ions

and phosphate ions from the tooth tissue.

B. removal of the smear layer and a modification of its superficial layer to form a hybrid layer.

C. creation of a micromechanical connection between the material and the tooth tissue.

D. use of retention grooves.

E. treating the tooth with a conditioner releases organic components from the tooth enamel.

Question nr 413

Which of the following intracanal dressings is a medicament of choice, with strong alkaline pH and the ability to dissolve remnants of necrotic tissue?

A. camphorated parachlorophenol.

B. calcium hydroxide.

C. glutaraldehyde.

D. formocresol.

E. glycocorticosteroid.

Question nr 414

How long is the cutting part of a rotary root canal instrument, if the total length of the instrument without the grip is 21 mm?

A. 20 mm.

B. 19 mm.

C. 18 mm.

D. 17 mm.

E. 16 mm.

Question nr 415

Indicate the true statements concerning secondary caries:

1) it is primary caries located at the margin of a restoration;

- 2) it is caused by metabolic activity in the biofilm developing on the tooth surface;
- 3) it can't be arrested by regular removal of the biofilm or fluoride topical application;
- 4) it develops due to the remains of demineralized dentin on the floor of the cavity.

The correct answer is:

- A.** 1,2.
- B.** 1,3.
- C.** 3,4.
- D.** 2,4.
- E.** 2,3.

Question nr **416**

Which of the canal irrigants are recommended for removing of organic debris from the root canal?

- A.** sodium hypochlorite and saline.
- B.** hydrogen peroxide and isopropyl alcohol.
- C.** chlorhexidine and EDTA.
- D.** chlorhexidine and sodium hypochlorite.
- E.** hydrogen peroxide and sodium hypochlorite.

Question nr **417**

Indicate problems connected with the use of fourth- and fifth-generation adhesive systems:

- 1) too deep etching;
- 2) overdrying of dentin;
- 3) overwetting of dentin;
- 4) necessity of using self-etching primers.

The correct answer is:

- A.** 1,2,3.
- B.** 1,2,4.

C. 2,3,4.

D. 1,3,4.

E. 2,4.

Question nr 418

Which of the following are characteristic reactions of the dentin-pulp complex to pathogenic factors?

- 1) tubular sclerosis within the dentin in the form of a transparent zone;
- 2) reactionary dentine formation at the border between the dentine and the pulp;
- 3) formation of a dentinal bridge;
- 4) pulp inflammation;
- 5) reparative dentine formation.

The correct answer is:

A. 1,2,3.

B. 1,2,4.

C. 2,3,4.

D. 2,3,5.

E. 3,4,5.

Question nr 419

Indicate the true sentence concerning thermal pulp tests:

A. before performing a heat test with warmed gutta-percha the tooth should be covered with vaseline.

B. cold test can be performed with a small ball of cotton wool soaked with ethyl alcohol.

C. healthy pulp reacts to thermal stimuli with pain that stops after a few minutes.

D. intense and prolonged response to heat with no reaction to cold may indicate reversible pulpitis.

E. lateral teeth usually show more sensitivity to cold stimuli than anterior teeth.

Question nr **420**

Which of the following intracanal medicaments shows antimicrobial activity, alkaline pH and dissolves necrotic tissue remnants, bacteria and their byproducts?

- A.** chlorhexidine.
- B.** corticosteroids.
- C.** calcium hydroxide.
- D.** phenols.
- E.** aldehydes.

Question nr **421**

Indicate the true statement concerning the smear layer formed during endodontic treatment:

- 1) it is a layer of organic and inorganic debris covering the root canal walls after their mechanical preparation;
- 2) smear layer may impede the penetration of interappointment disinfectants;
- 3) presence of the smear layer provides better adhesion of obturation materials to the root canal walls;
- 4) removal of the smear layer reduces leakage in the obturated canal;
- 5) EDTA is the most effective irrigating solution removing the smear layer completely.

The correct answer is:

- A.** 1,2,3.
- B.** 1,2,4.
- C.** 2,3,4.
- D.** 1,2,5.
- E.** 1,4,5.

Question nr **422**

What is the origin of nerve fibers responsible for the regulation of pulpal blood flow?

- A.** vegetative system.

B. sensory component of the second and third branch of the trigeminal nerve.

C. motor component of the second and third branch of the trigeminal nerve.

D. sensory and motor component of the second and third branch of the trigeminal nerve.

E. the motor component of the second and third branch of the trigeminal branch and the vegetative system.

Question nr **423**

Which teeth group is predominantly affected by dens evaginatus?

A. upper central incisors.

B. upper lateral incisors.

C. permanent upper molars.

D. lower premolars.

E. milk molars.

Question nr **424**

Which pH level is critical for the dentin?

A. 4.5.

B. 5.5.

C. 6.0.

D. 7.0.

E. 11.0.

Question nr **425**

Beginning with a file in size 60, the diameter of the tool tip at D_0 increases (relative to the next tool) by:

A. 0.01 mm.

B. 0.05 mm.

C. 0.10 mm.

D. 0.15 mm.

E. 0.50 mm.

Question nr **426**

Indicate **the false** statement concerning an enamel carious lesion:

A. white spot is the earliest clinical evidence of caries on the smooth enamel surface.

B. white spot is chalky white, opaque areas on the enamel surface.

C. remineralized enamel in arrested caries is more prone to acid attacks than unaffected enamel.

D. the dark color of an inactive carious lesion in the enamel is caused by trapped organic debris.

E. incipient caries in the enamel can be stopped.

Question nr **427**

The model of the root canal system occurring in a single root given in the figure below, in which two root canals leave the pulp chamber, joining in the root and again dividing into two canals near the apex into two separate, distinct canals with separate apical foramina, is classified by Vertucci as type:



A. VI.

B. V.

C. IV.

D. III.

E. II.

Question nr 428

Which of the following pairs constitutes the right set of diagnosis and recommended treatment:

- A.** reversible pulpitis - amputation of the crown portion of the pulp.
- B.** irreversible pulpitis - antiseptic root canal treatment.
- C.** pulp necrosis - pulp extirpation performed under local anesthesia and a single-visit root canal treatment.
- D.** acute apical abscess - general antibiotic therapy, pulp extirpation performed under local anesthesia and a single-visit root canal treatment.
- E.** chronic apical abscess - antiseptic root canal treatment.

Question nr 429

Which of the listed periapical conditions may be associated with a vital tooth?

- A.** condensing osteitis.
- B.** radicular cyst.
- C.** periapical granuloma.
- D.** chronic apical periodontitis.
- E.** acute apical abscess.

Question nr 430

Which of the following medications may be a cause of hyposalivation or dry mouth (xerostomia)?

- 1) antidepressants;
- 2) antihypertensive agents;
- 3) diuretics;
- 4) antihistamines;
- 5) tetracycline, doxycycline, iron preparations, and non-steroidal anti-inflammatory drugs.

The correct answer is:

- A. 1,2,3,5.
- B. 1,2,3,4.
- C. 1,3,4,5.
- D. 1,2,4,5.
- E. 2,3,4,5.

Question nr **431**

Which of the following concerning the acquired pellicle (pellicle) is true?

- 1) it is an acellular, protein membrane seal;
- 2) it is an inorganic membrane seal precipitating from saliva minerals;
- 3) its initial colonizer is *S. sanguinis*;
- 4) it forms in 24-48 hours after mechanical cleaning of teeth.

The correct answer is:

- A. 1,3.
- B. 1,4.
- C. 2,3.
- D. 2,4.
- E. 3,4.

Question nr **432**

Indicate the true statements concerning the usage of spreaders in the endodontic treatment:

- 1) they are used in the filling method with thermoplastic obturator Thermafil;
- 2) they are used for vertical condensation of gutta-percha;
- 3) stainless steel spreaders are used to fill canals with a significant degree of curvature;
- 4) first spreader should be inserted into the root canal to a depth of 1-2 mm shorter than the working length;
- 5) they are available with handles or as finger-held instruments.

The correct answer is:

- A. 1,3.
- B. 2,3.

C. 2,5.

D. 3,4.

E. 4,5.

Question nr **433**

Select the **false** sentences concerning the elements of saliva:

- 1) lactoferrin binds free iron;
- 2) lysozyme presents antimicrobial activity;
- 3) secretory immunoglobulin A and mucins present agglutinative activity;
- 4) lysozyme and secretory immunoglobulin A are salivary enzymes;
- 5) lysozyme, lactoferrin and secretory immunoglobulin A support remineralisation.

The correct answer is:

A. 1,5.

B. 1,3.

C. 3,4.

D. 4,5.

E. 2,5.

Question nr **434**

What is the role of saliva lipases?

- A. catalysis in the hydrogen-peroxide system.
- B. release of peptidoglycans.
- C. hydrolysis of triglycerides.
- D. increase in the availability of oligosaccharides.
- E. agglutination of bacteria.

Question nr **435**

Which of the following **is not** radiolucent on X-ray?

- A. periapical granuloma.

- B. radicular cyst.
- C. external resorption.
- D. condensing osteitis.
- E. mental foramen.

Question nr **436**

Which of the following **does not** worsen chronic apical periodontitis?

- A. causal tooth injury.
- B. patient's immune dysfunction.
- C. closing the caries cavity with food debris.
- D. tissue damage during root canal treatment.
- E. fistula formation.

Question nr **437**

Indicate the true statements on the inflammatory cervical resorption:

- 1) patient, in most cases, reports severe pain from the tooth;
- 2) is most often seen as a complication of in-office teeth whitening;
- 3) is an example of internal resorption;
- 4) can be clinically seen as a pink spot (pink tooth);
- 5) surgical treatment is a common procedure in its treatment.

The correct answer is:

- A. 1,2,3.
- B. 3,4,5.
- C. 1,2.
- D. 4,5.
- E. all the above.

Question nr **438**

Indicate the true statements concerning resistance form in cavity preparation:

- 1) it provides the resistance of tooth tissues to destruction during mastication

of the food;

2) it provides the resistance of the filling to destruction during mastication of the food;

3) it provides better retention of the restoration in the cavity;

4) resistance form can be achieved by rounding margins or sharpening angles of the cavity;

5) resistance form can be achieved by slightly converging cavity walls towards the occlusal surface.

The correct answer is:

A. 1,3,5.

B. 1,2,5.

C. 1,2,4.

D. 3,4,5.

E. 2,3,4.

Question nr **439**

Sclerotic dentine:

A. contains fewer mineral substances than primary dentine.

B. is formed below the lesion on the pulp chamber wall.

C. is connected with remineralization of peritubular dentine.

D. is not formed in teeth with atypical caries.

E. can be remineralized by fluoride compounds.

Question nr **440**

Which of the following methods **is not** recommended for the teeth with incompletely formed roots?

A. vital pulp extirpation.

B. coronal pulpotomy.

C. deep pulpotomy.

D. devitalized pulp extirpation.

E. pulpectomy.

Question nr **441**

Which of the following **is not** a cause of false-positive response of the pulp to electric test?

- A. contact of the active electrode with the gum or amalgam restoration.
- B. patient anxiety.
- C. calcified canals.
- D. wet tooth covered by saliva.
- E. liquefaction necrosis.

Question nr **442**

The preventive resin restoration is a minimally invasive procedure proposed by Simonsen and it is a method combining:

- A. minimally invasive preparation of a carious focus with painting the tooth surface with fluoride varnish.
- B. fissure sealing with ART method.
- C. fissure sealing with painting the tooth surface with fluoride varnish.
- D. mechanical fissure preparation with painting the tooth surface with fluoride varnish.
- E. fissure sealing with minimally invasive preparation of a carious focus filled afterwards with composite.

Question nr **443**

Which of the following salivary components **does not** show antimicrobial activity?

- A. lysozyme.
- B. lactoferrin.
- C. peroxidase.
- D. lipase.

E. agglutinins.

Question nr **444**

This type of resorption is considered to be a physiological process to repair minor damage of the external surface of the root. Sometimes it occurs during orthodontic treatment. It does not give clinical symptoms, most often is invisible on x-ray images. At root surfaces you may see small cavities in the cement, and in the superficial dentine layer, which are being repaired with new cement. What is the name of this type of resorption?

- A. invasive cervical resorption.
- B. inflammatory apical resorption.
- C. external replacement resorption.
- D. physiological resorption.
- E. external surface resorption.

Question nr **445**

Which of the following changes **does not** occur in aging patients?

- A. decrease in the amount of collagen.
- B. decrease in the number of cells.
- C. decrease in the number of blood vessels.
- D. pulp calcification.
- E. decrease in the activity of odontoblasts.

Question nr **446**

After the rubber dam is applied to the tooth that is going to undergo endodontic treatment, the operating field should be disinfected with the use of:

- A. chloroform.
- B. saline.
- C. sodium hypochlorite.

D. citric acid.

E. after the rubber dam is applied to the tooth, there is no need to disinfect the operating field.

Question nr **447**

Indicate the correct definition of abfraction:

A. wedge-shaped defect with sharp margins located on the enamel-cementum border.

B. mechanical wear of incisal edges of teeth as a result of parafunctional movements of the mandible.

C. wear or loss of a tooth surface caused by chemical processes.

D. loss of dental hard tissues caused by a direct friction between the tooth and external objects.

E. biological process of tooth degradation.

Question nr **448**

From the following factors select those which determine the shape of the resistance form obtained during the preparation of a caries cavity for amalgam filling:

1) dentine support of the enamel;

2) slightly convergent configuration of the walls towards the inlet of the cavity;

3) filling thickness proportional to its surface extensiveness;

4) elimination of right and acute angles;

5) additional cuts in the form of grooves and slots.

The correct answer is:

A. 1,2,3.

B. 1,3,4.

C. 1,3,5.

D. 2,3,4.

E. 2,4,5.

Question nr **449**

The mechanism of GLUMA desensitizer action is based on:

- A.** precipitation of strontium-apatite complexes.
- B.** deactivation of nerve fibres in the pulp.
- C.** precipitation of fluoroapatite on enamel surfaces.
- D.** protein denaturation.
- E.** nerve ending depolarization.

Question nr **450**

The presence of the so-called „cervical burnout” on dental radiographs indicates:

- A.** correct radiological tooth appearance.
- B.** caries on the contact surface of the crown.
- C.** circumferential caries of the root.
- D.** presence of toothbrush abrasion.
- E.** initial stage of external cervical resorption.

Question nr **451**

Which of the below mentioned root canal irrigants can be used as last due to its prolonged antibacterial activity?

- A.** sodium hypochlorite.
- B.** EDTA.
- C.** citric acid.
- D.** chlorhexidine.
- E.** hydrogen peroxide.

Question nr **452**

A young patient reported to the dentist for conservative treatment of tooth 37. Examination showed soft, reddish, cauliflower-like lesion protruding from vast cavity of the crown. Lesion is currently painless, but patients reports episodes of spontaneous pain in the past. Thermal pulp sensibility test

resulted in weakened response to cold. In course of which clinical situation can the above-mentioned lesion develop?

- A.** pulp necrosis.
- B.** irreversible pulpitis with vital pulp.
- C.** reversible pulpitis.
- D.** periapical abscess.
- E.** periapical granuloma.

Question nr **453**

Which of the below mentioned conditions is an indication for indirect pulp capping, on the assumption that there is a normal response to pulp vitality test?

- A.** accidental pulp injury.
- B.** accidental pulp exposure.
- C.** deep caries.
- D.** carious pulp exposure.
- E.** traumatic pulp exposure.

Question nr **454**

What material can be applied directly to the pulp in a case of pulpotomy?

- 1) glass ionomer;
- 2) calcium hydroxide non-hardening;
- 3) zinc oxide with eugenol;
- 4) MTA.

The correct answer is:

- A.** 1,2.
- B.** 1,3.
- C.** 2,3.
- D.** 2,4.
- E.** 3,4.

Question nr **455**

Indicate the true sentences regarding the electrical test used in the examination of the tooth pulp state:

- 1) electro-excitability testing should not be performed on patients with a pacemaker;
- 2) total necrotic teeth show a reduced excitability threshold;
- 3) examination with this method does not determine the type of pulpitis;
- 4) a false positive result may be due to the presence of mineral deposits in the tooth cavity.

The correct answer is:

- A.** 1,3.
- B.** 1,4.
- C.** 2,3.
- D.** 2,4.
- E.** 3,4.

Question nr **456**

Choose the proper name for the process of wear of the hard tissues of the teeth, which is manifested by shortening of the crowns of the teeth, wear of the incisal edges of the anterior teeth and cusps of the posterior teeth, and accompanies bruxism as a symptom:

- A.** abrasion.
- B.** attrition.
- C.** abfraction.
- D.** erosion.
- E.** Black's class VI.

Question nr **457**

Choose correct sentences concerning the tunnel cavity preparation:

- 1) it is used in vestibular or lingually inclined teeth;
- 2) allows to maintain unmined marginal edge;
- 3) can be used in case of primary caries on the proximal surface of the posterior teeth;

4) access cavity preparation is achieved from the vestibular or lingual surface.

The correct answer is:

A. 1, 2.

B. 1, 3.

C. 2, 3.

D. 2, 4.

E. 3, 4.

Question nr **458**

Indicate **false** information regarding adhesion to enamel and dentin:

A. dentin etching removes the smear layer, decalcifies the superficial dentin and dentinal tubules.

B. hybrid layer is created by combining the resin with collagen through monomer cross-links.

C. treating the tooth surface with a conditioner improves the bonding efficiency of the glass ionomer to hard tooth tissues.

D. the ability of the adhesive to wet the surface depends on the contact angle of the fluid with the solid surface.

E. good wetting occurs when the angle of the fluid with the solid surface is above 90°.

Question nr **459**

Indicate correct sentences concerning the radiating pain:

1) it is characteristic of irreversible pulpitis;

2) due to pain radiation the patient is able to specify the side, in which the pain originates, but not always determine if the causal tooth is located in maxilla or mandible;

3) pain caused by tooth 35 can radiate to eye and temple;

4) pain caused by tooth 46 can radiate to ear;

5) pain caused by tooth 26 can radiate to occiput and neck.

The correct answer is:

A. only 2.

- B.** 1, 5.
- C.** 2, 3, 4.
- D.** 3, 4, 5.
- E.** 1, 2, 4.

Question nr **460**

Physiological secondary dentine:

- A.** forms due to exposure to harmful factors.
- B.** builds up unevenly, only on certain walls of tooth cavity.
- C.** has less regular structure than pathological secondary dentine.
- D.** comprises properly formed dentinal tubules.
- E.** is separated from the primary dentine by dark line.

Question nr **461**

Type III according to Vertucci's classification indicates following root canal configuration:

- A.** one single, wide canal extending from the pulp chamber, dividing into two, and then merging into one in the apex area.
- B.** single canal that begins centrally in the pulp chamber and ends in the apex area with one apical foramen.
- C.** single canal extending from the pulp chamber, dividing short of the apex into two separate and distinct canals with separate apical foramina.
- D.** two separate and distinct canals extending from the pulp chamber, joining short of the apex to form one canal.
- E.** two separate and distinct canals extending from the pulp chamber to the apex with two separate apical foramina.

Question nr **462**

Indicate correct sentence regarding the compomers:

- A.** can be used only in restorations of anterior teeth.

B. consist of approximately 80% glass ionomer and approximately 20% resin components.

C. characterise in better aesthetics than glass ionomers.

D. require the same chemical preparation of the cavity as glass ionomers.

E. the amount of fluoride ions release is lower than in the composite materials.

Question nr 463

Indicate a solution for removal of smear layer from the root canal:

A. NaCl solution for removing the organic part of smear layer and EDTA for inorganic part.

B. NaOCl solution for removing the inorganic part of smear layer and EDTA for organic part.

C. NaOCl solution for removing the organic part of smear layer and EDTA for inorganic part.

D. sodium edetate solution for removing the inorganic part of smear layer and citric acid solution for removing the organic part.

E. citric acid solution for removing the inorganic part of smear layer and hydrogen peroxide for removing the organic part.

Question nr 464

Choose correct sentences concerning the thermocatalytic technique of bleaching:

1) this method can be used at home, by the patients themselves or in the dental office by the staff;

2) the procedure can be performed during one visit;

3) during the procedure 30% perhydrol (hydrogen peroxide) solution is used;

4) light source should be pointed towards the tooth, which should be exposed for approximately 30 minutes at a time;

5) the procedure should be performed only in the presence of lignin rolls, due to the fact that dental dam degenerates when exposed to perhydrol.

The correct answer is:

A. only 1.

B. 2, 3.

C. 1, 4.

D. 2, 3, 5.

E. 2, 4, 5.

Question nr 465

In case of a total luxation (avulsion) of a permanent tooth with completely formed apex, which after knocking out was preserved in dry environment (up to 30 minutes), replanted tooth should be stabilized for:

A. 7-14 days.

B. 3-4 weeks.

C. 6-12 weeks.

D. 18 weeks.

E. none of the above mentioned.

Question nr 466

If the value of so-called efficiency treatment index is equal to 100%, it means that:

A. none of the carious teeth has been filled.

B. all carious teeth have been filled.

C. all carious teeth have been extracted.

D. the patient does not have any teeth (edentulous patient).

E. the number of carious teeth (which have not been yet filled) equals the number of carious teeth that have been filled.

Question nr 467

Choose correct sentences concerning the internal resorption:

- 1) symptoms present both clinically and radiologically, are the evidence of process' advancement;
- 2) in early stages the pulp reacts normally to stimuli;
- 3) only the advanced stages are the indications for endodontic treatment;
- 4) thermal method of root canal filling is indicated in such cases;
- 5) such lesions have uneven, jagged edges and do not connect to the pulp

chamber, but only the canal wall.

The correct answer is:

- A. 1, 2, 5.
- B. 1, 2, 4.
- C. 3, 4, 5.
- D. 1, 3, 4.
- E. 1, 4, 5.

Question nr **468**

For caries diagnostics, DIAGNOdent uses the phenomenon of:

- A. laser radiation in the low-infrared.
- B. fluorescence.
- C. electric current flow through the tooth.
- D. transillumination.
- E. opalescence.

Question nr **469**

Choose **false** sentence/s concerning the intrapulpal injection technique:

- 1) the needle needs to be loosely positioned in the chamber;
- 2) this technique cannot be used as the sole and primary anesthesia in case of endodontic treatment;
- 3) it is painful;
- 4) it can be performed after the pulp has been exposed;
- 5) it can be performed using a carpule syringe.

The correct answer is:

- A. only 1.
- B. 1, 5.
- C. 2, 3.
- D. 3, 4.
- E. 2, 5.

Question nr **470**

Choose **false** sentences concerning the composites:

- A.** change of colour can be caused by material's oxidizing.
- B.** monomers added to the matrix reduce the viscosity of oligomer resin.
- C.** most commonly added fluorine compounds are: fluorosilicate, fluorine glass and ytterbium fluoride.
- D.** cohesion agents in composites are silanes, and titanium and zirconium compounds.
- E.** in microhybrid composites the size of filler particles is approximately 0,01-0,1 μm .

Question nr **471**

Choose correct sentences concerning the isolation of dental treatment area:

- 1) the use of Dry Tips is considered an absolute isolation method, as it provides the complete coverage of parotid orifice;
- 2) use of dental dam is contraindicated in case of an epileptic patient;
- 3) butterfly clamps are used for isolating the front teeth;
- 4) silicone rubber used in dental dam is thicker than latex one, and is recommended for endodontics;
- 5) OptiDam is a kind of liquid, light-cured dental dam used in sealing the conventional dam.

Correct answer is:

- A.** 1, 2, 3.
- B.** 2, 4, 5.
- C.** 1, 2, 5.
- D.** 1, 3, 5.
- E.** 2, 3, 5.

Question nr **472**

Root caries lesion of depth < 0.5 mm intended for non-invasive treatment, according to Billings index, belongs to class:

- A.** I.

B. II.

C. III.

D. IV.

E. V.

Question nr 473

Choose **false** statement regarding the dentine hypersensitivity:

A. its treatment aims to partially or totally close the dentine tubules.

B. it can be caused by osmotic, thermic or mechanical stimuli.

C. it is often accompanied by gum recession.

D. it is characterized by acute pain, lasting for several dozen minutes after exposure to a given stimulus.

E. it occurs in case of exposed dentine tubules.

Question nr 474

Choose correct combination of etiologic factors and changes they foster:

1) bacteria;

2) acidic food and drinks;

3) excessive and incorrect teeth brushing;

4) excessive use of tooth picks;

5) gastroesophageal reflux.

a) erosion;

b) caries;

c) abrasion.

The correct answer is:

A. a-2,5; b-1; c-3,4.

B. a-1,2; b-3; c-4,5.

C. a-2,3; b-5, c-1,4.

D. a-1; b-2,3,4; c-5.

E. a-4,5; b-1,2; c-3.

Question nr **475**

Which of the below mentioned saliva ingredients **does not** demonstrate antibacterial activity?

- A. lysozyme.
- B. lactoferrin.
- C. immunoglobulin A.
- D. agglutinin.
- E. statherin.

Question nr **476**

A 20-year-old patient reported to the dental office for a check-up. During intra-oral examination dental plaque was observed in the cervix area of tooth 14 and 24. After cleansing of the teeth, white stains of chalky, opaque appearance (without disrupting the continuity of enamel) were observed, in the same regions. They were visible without drying the tooth surface. Indicate correct management:

- A. observation only.
- B. remineralisation.
- C. mechanical removal of stained tissue and subsequent composite filling.
- D. mechanical removal of stained tissue and subsequent amalgam filling.
- E. mechanical removal of stained tissue and subsequent temporary zinc oxide with eugenol filling.

Question nr **477**

The hand endodontic file with red handle and triangular graphic mark is:

- A. K-type file number 25.
- B. reamer, number 30.
- C. reamer, number 55.
- D. K-type file, number 30.

E. Hedstroem file, number 25.

Question nr **478**

Select the **incorrect** statement regarding dental pain:

- A. necrosis coverage of the entire dental pulp increases pain.
- B. night pain may accompany both early and advanced forms of pulpitis.
- C. pain from the upper tooth radiates to the temple and eye.
- D. the painful symptoms of pulpitis are caused by the presence of an exudate.
- E. recent pain is specific to acute reversible pulpitis.

Question nr **479**

Select the **incorrect** statement regarding enameloblastoma:

- 1) occurs mainly in the lateral region of the mandible;
- 2) does not show characteristic features on X-ray in the final stage of development;
- 3) does not cause root resorption of root canal treated teeth;
- 4) requires surgical treatment.

The correct answer is:

- A. 1,2.
- B. 2,3.
- C. 3,4.
- D. 1,3.
- E. 2,4.

Question nr **480**

Select the correct statement regarding rinsing agents used in endodontic treatment:

- A. EDTA inhibits bacterial cell adhesion, does not remove smear layer, and does not neutralize bacterial toxins.
- B. isopropyl alcohol with silver nanoparticles has a strong bacteriostatic effect but discolors hard dental tissue.

- C. chlorhexidine effectively eliminates *E. faecalis* but has no antifungal properties.
- D. chelating compounds are effective in softening of dentine.
- E. sodium hypochlorite is activated by contact with biological material and dissolves inorganic tissue.

Question nr **481**

The differential diagnosis of an osteolytic focus located in the anterior aspect of the mandible **should not** include:

- A. metastasis of breast cancer.
- B. presence of an ameloblastoma.
- C. presence of a root cyst.
- D. metastasis of the thyroid cancer.
- E. presence of periapical bone dysplasia.

Question nr **482**

36 y.o. patient referred to the dentist due to spontaneous pain, lasting for 12 hours, occurring during biting. On the previous day, a one-visit root canal treatment of tooth 12 was performed, on account of planned prosthetic restoration of said tooth crown. X-ray positively verified accuracy of the treatment. The right cause of action in such case is:

- A. initiating the revision of the rct of tooth 12.
- B. implementation of antibiotic and analgesic therapy.
- C. recommendation for CBCT examination.
- D. considering the need of performing apical root resection.
- E. recommendation for temporary observation and taking pain medication.

Question nr **483**

Which therapeutic method is recommended for the treatment of a carious lesion defined by the site and stage classification of Lasfargues et al.as 2.1.?

A. Box(slot) preparation, flow composite application.

B. PRR-1 technique.

C. PRR-2 technique.

D. application of remineralization products.

E. tunnel preparation, amalgam application.

Question nr **484**

Select the correct statement about side effects observed after radiotherapy of head and neck area:

- 1) dental caries;
- 2) dental attrition;
- 3) dentine hypersensitivity;
- 4) external and internal resorption;
- 5) dryness of oral cavity;
- 6) tooth discoloration.

The correct answer is:

A. 1,2,6.

B. 2,3,5.

C. 1,4,6.

D. 1,4,5.

E. 4,5,6.

Question nr **485**

Select the correct statement about type C canals:

- 1) they are most common in maxillary second molars;
- 2) in teeth with type C canals, the chamber floor may extend below the tooth's neck;
- 3) type C category I canals are two canals forming a full letter C on the chamber floor;
- 4) the fusion of roots into a single cone on x-ray may suggest the presence of type C canals.

The correct answer is:

A. 1,2.

B. 2,3.

C. 3,4.

D. 1,3.

E. 2,4.

Question nr 486

Bioactive materials used in pulp biological treatment should be characterized by:

- 1) high biocompatibility;
- 2) low biocompatibility;
- 3) high mutagenicity;
- 4) good adhesion.

The correct answer is:

A. 1,2.

B. 2,3.

C. 3,4.

D. 1,3.

E. 1,4.

Question nr 487

Select the correct statement regarding the phenomena occurring when canals are filled with thermoplastic technics:

- A.** sustained temperature increase of 10°C above body temperature for more than 1 min can lead to irreversible changes in periodontium.
- B.** dentine and root cement are good temperature conductors.
- C.** the temperature rise in different parts of the canal is the same.
- D.** the thickness of the canal walls has no effect on heat conduction.
- E.** the presence of sealant does not affect the temperature rise at the root surface.

Question nr 488

Select the correct statement regarding the DI-FOTI diagnostic method:

- A. the method uses the phenomenon of fluorescence.
- B. the method uses visible light.
- C. the presence of carious demineralization increases the transmission of light into the tissue.
- D. the method allows quantitative assessment of demineralization.
- E. shows comparable sensitivity in lesion detection to radiographic examination, but higher specificity.

Question nr **489**

Select the **incorrect** statement about cariogenic bacteria:

- A. use saliva glycoproteins in their metabolism.
- B. it does not have the ability to actively transport sugar.
- C. develop protective mechanisms against the phenomenon of 'substrate-accelerated death'.
- D. produce soluble polysaccharides.
- E. have the ability to regulate the rate of glycolysis.

Question nr **490**

Giomer is:

- A. a polyacid-modified composite with organically modified ceramics.
- B. a resin-modified glass-ionomer with organically modified ceramics.
- C. a glass-ionomer created in PRG technology.
- D. a composite and glass-ionomer hybrid created in S-PRG or F-PRG technology.
- E. bulk-fill composite.

Question nr **491**

Indicate correct statements regarding adhesion of composites:

- 1) enamel etching with 37% phosphoric acid allows to achieve chemical microretention of resin to enamel;

- 2) crosslinking of monomers with collagen occurs in the hybrid layer of dentin;
- 3) dentin etching removes the smear layer, decalcifies the superficial layer of dentin and dentin tubules;
- 4) OptiBond Solo Plus belongs to the 7th generation of self-etching systems;
- 5) smear layer is formed after mechanical cutting of dentin at depths of 0.5 to 5 μ m.

- A. 1,2,3.
- B. 2,4,5.
- C. 1,2,5.
- D. 1,3,5.
- E. 2,3,5.

Question nr **492**

Which of the below mentioned steps of bleaching non-vital teeth is **incorrect**?

- A. cleaning the surface of bleached and surrounding teeth.
- B. determining the colour before bleaching and performing the photographs of teeth.
- C. rubber dam placement.
- D. performing the chamber access and removing the root canal filling to the depth of 5 to 10 mm.
- E. securing the gutta-percha in the root canal with flow material.

Question nr **493**

Which of the below mentioned materials used in vital pulp therapy has the lowest pH?

- A. Calasept.
- B. ProRoot MTA.
- C. Dycal.
- D. Calxyl.

E. Biopulp.

Question nr 494

Indicate correct statements regarding the smear layer:

- 1) it is present on the surface of dentin, only in the region of the crown;
- 2) it is present on the surface of crown and root dentin after tooth preparation;
- 3) it can be removed by mechanical preparation;
- 4) it can be removed by chemical agents;
- 5) it consists only of inorganic components;
- 6) it consists of organic and inorganic components.

A. 1,3,5.

B. 1,3,6.


C. 1,4,5.

D. 2,4,5.

E. 2,4,6.

Question nr 495

Indicate the most common length of hand files marked as L1 in ISO standardization:



A. 16 mm.

B. 21 mm.

C. 25 mm.

D. 28 mm.

E. 31 mm.

Question nr 496

Indicate correct statement/s regarding the anatomy of maxillary canine:

- 1) canine is the longest human tooth;
- 2) it has an oval cross-section along the entire length of the root with the oval elongating towards the vestibular-palatal direction;
- 3) outline of chamber access has the shape of an ellipse; in elder patients it is bigger and more elongated in the direction of incisal edge;
- 4) straight path of the canal occurs in about 90% of cases. The root canal of the canine is rarely curved.

A. only 1.

B. only 3.

C. 1,2.

D. 1,3,4.

E. 1,2,4.

Question nr 497

If working part of the endodontic file has the conicity of 2%, it means that the file is expanding on each millimeter by:

A. 0.22 mm.

B. 0.20 mm.

C. 0.12 mm.

D. 0.02 mm.

E. 0.002 mm.

Question nr 498

Indicate correct statements regarding the root caries:

- 1) it is characterized by slower progress than enamel caries;
- 2) it develops in teeth with healthy periodontium, without gum recession;
- 3) it occurs more often in elderly;
- 4) such cavities have higher tendency for vastness than depth, with diameter close to U;
- 5) root surface is prone to faster dental plaque accumulation.

A. 1,3,5.

B. 2,3,5.

C. 3,4,5.

D. 1,3,4.

E. 1,4,5.

Question nr **499**

What is the clinical term of regions of dentition colonized by bacteria, which are not affected by mechanical factors?

- 1) retention;
- 2) stagnation;
- 3) bacterial succession;
- 4) control of bacterial plaque.

A. 1,2.

B. 2,3.

C. 3,4.

D. 1,3.

E. 2,4.

Question nr **500**

Indicate the earliest noticeable clinical manifestation of caries:

- A.** carious lesion.
- B.** enamel cavity.
- C.** white spot.
- D.** brown spot.
- E.** cloudy spot.

Question nr **501**

Indicate **false** statements about root caries:

- 1) exposed cementum and dentin, are less mineralized than enamel and more susceptible to carious agents;
- 2) the microflora of root caries is different from the microflora associated with

enamel caries;

3) the critical pH at which root dentin dissolution occurs is 5.0–5.5;

4) the freshly exposed root surface has a lower fluoride concentration than enamel.

A. 1,2.

B. 2,3.

C. 3,4.

D. 1,3.

E. 1,4.

Question nr **502**

The teeth are characterized by iridescence and are amber-brown in color. Enamel crumbles easily and is prone to wear. RTG shows obliteration of dental cavities and shortened roots of permanent teeth". Which disorder is described above?

A. hypoplasia enameli.

B. discoloratio.

C. amelogenesis imperfecta.

D. dentinogenesis imperfecta.

E. dysplasio dentini.